

Techniques, Safety, and Therapeutic Effect of Percutaneous Cryoablation for Patients with Hepatocellular Carcinoma

Chunping Wang, MD; Yongping Yang, MD*

Center of Therapeutic Research for Hepatocellular Carcinoma, Beijing the 302nd Hospital, Beijing, China

Hepatocellular carcinoma (HCC) is the third most common cause of cancer-related deaths worldwide and the second most common cause in China. The rate of resection of HCC is limited to 20-30%. Therefore, various local ablative therapies such as radiofrequency ablation (RFA), percutaneous cryoablation (PC), microwave, and percutaneous ethanol injection therapy, which play an important role in the treatment of HCC, have been developed [1]. Recently, PC, a local ablative therapy, has been developed with several advantages (such as ability to produce larger and more precise zones of ablation) over RFA and other thermal ablation treatments. This review mainly focuses on the indications, techniques, patient management, safety, and efficacy associated with PC for patients with HCC.

[N A J Med Sci. 2016;9(2):66-70. DOI: 10.7156/naajms.2016.0902066]

Key Words: hepatocellular carcinoma, percutaneous cryoablation, necrocytosis

HISTORY OF CRYOTHERAPY

In the early days, cryotherapy was used only in laparotomy due to the bulky size of the system, use of liquid nitrogen as a refrigerant, and various complications, which resulted in sluggishness in the use of cryotherapy technique for about 200 years. In 1998, emergence of modern cryoablation equipment and argon-helium surgery system (Endocare Corporation, Irvine, CA) has brought revolutionary advances in minimally invasive cryosurgery and was deemed as the duration of recovery of PC for tumor clinically. Since endocare argon-helium surgery system was introduced in 1999, China has accumulated abundant clinical experience in treating lung, kidney, prostate, and liver cancer. In 2002, the American Medical Association designated PC as the preferred treatment for prostate cancer; in 2010, the American Urological Association issued the Best Practice Statement of Cryotherapy for Renal Carcinoma and recommended PC; in 2010, the National Health and Family Planning Commission of the People's Republic of China designated PC and RFA as local treatment options for HCC in the face of normalized diagnosis and treatment; in 2012, the National Comprehensive Cancer Network recommended PC to the treatment guidelines for non-small cell lung cancer; and in 2012, European Association for the Study of the Liver and European Society for Medical Oncology jointly renewed management guideline for HCC and believed that PC was the biggest challenge to RFA.¹

NECROCYTOSIS MECHANISM OF PC

Cryoablation region comprises the central coagulation necrosis and damaged regions in the peripheral tissues. Rapid direct necrosis mechanism of central cells includes mechanical and permeability damage caused by intra- and extracellular ice crystals, and dehydration of cell rupture, respectively.³⁻⁷ The damage of the peripheral regions is mainly due to the secondary injury related to cryoablation including hypoxia and activation of programmed cell death, which are caused by disrupted small vessels.⁸ Recent studies have indicated that apoptosis is associated with local recurrence.⁹⁻¹¹ Thermal-cold cycles twice can improve the effectiveness of cryoablation and the rate of control of local tumor in the therapeutic process. Some evidences have shown that single thermal-cold cycle can hardly inactivate the tumor with a stronger anti-indemnification as compared with normal tissue, which may due to the characteristics of tumor fibrous tissue.¹²⁻¹⁴ Cryoablation mechanism¹⁵ is provided in **Figure 1**.

RATIONALE OF PC FOR HCC

The rationale of PC for HCC is as follows: (1) rich experience of RFA for HCC and (2) outstanding clinical effect of PC for other solid tumors including kidney, prostate, and lungs. The efficiency of RFA may be associated with the characteristics of cirrhotic and tumor tissues. When capsule or false capsule exists between the soft tissue of tumor and juxtacancerous cirrhotic tissue, radiofrequency heat should be packed in tumor tissue to produce oven effect, which could improve the necrotizing of tumor treatment but limit the therapy for microsatellite of tumor.¹⁶ Oven effect does not exist in PC as cryoablation mechanism has no effect on the energy and efficiency. Therefore, PC can sufficiently

Received 02/12/2015; Revised 03/03/2016; Accepted 03/07/2016

*Corresponding Author: Center of Therapeutic Research for Hepatocellular Carcinoma, Beijing the 302nd Hospital, Beijing, 100 Xisi Huan Middle Road, Beijing, China 100039.
Tel: 0086 (10) 6387-9193, Fax: 0086 (10) 6387-9193.
(Email: yongpingyang@hotmail.com)

treat the microsatellite of tumor margin as well as juxtacancerous microsatellite. PC has seldom been studied in other countries except China, but it is a potential treatment method. Previously, it was difficult to perform percutaneous pathway because the diameter of cryoprobe, which uses liquid nitrogen as a refrigerant, was too large. Nowadays, the cryoprobe with a smaller diameter (15-17G, 3 mm=11G) makes it possible to perform PC, which has been given close attention by western researchers. In comparison to thermal ablation including RFA, PC has some advantages. First, the ice ball formed in the process of PC can be clearly monitored using ultrasonography (US),¹⁷ computed tomography (CT).¹⁷ and magnetic resonance imaging (MRI).¹⁸ Later a 1.1-mm edge, formed between the ice ball and liver tissue, can make the liver tissue with abundant moisture necrotic, which represents an isotherm of -20°C . Abundantly fibrotic tumor tissue can form an 8-mm border at the edge of the ice ball, which represents isotherm of -40°C . It is crucial to the treatment. The high visibility of ice ball ensures precision and safety of therapy, and the tissue gasification during thermal ablation process, which affects the observation of boundary between the area of therapy and adjacent tissue. Second, the concurrent placement of multiple probes can ablate the tumor with a 10-cm diameter.²⁰ Additionally, PC can reduce evident pain.²¹ PC focuses the risk of hemorrhage after cryoablation. In comparison to thermocautery probe path of thermal ablation, PC does not have this advantage. However, Shock et al²² did not find that PC could increase the risk of hemorrhage in normal liver tissue and had no report on cirrhotic tissue.

TECHNICAL FACTORS OF PC

The critical factors affecting the complication after tumor treatment include the place of cryoprobe, imaging monitor, patient management, and postoperative nursing. Local ablation strategy is to completely damage the tumor and normal tissue with 1 cm distance from the tumor. For the patients with cirrhosis-related HCC, ablation of peripheral normal liver tissue should be reduced properly.

Placement of Cryoprobe

The place and number depend on the shape and size of the tumor. Wang et al. and Hinshaw and Lee proposed 2-to-1 principle, which is deemed as an ideal place method.²³⁻²⁴ The number of cryoprobe is determined using the tumor size. Multiple cryoprobes can be placed simultaneously so that cryotherapy can produce larger ablation zone. Isothermal uniform field of -20°C or below -40°C caused by synergistic effect of multiple cryoprobes is able to inactivate tumor cell. The effect is superior to single cryoprobe treatment. It is hard to follow the 2-to-1 principle due to the rib. Generally, 2 or 3 cryoprobes are placed simultaneously. For the tumors with incomplete ablation, the place of cryoprobe can be changed to continue the treatment or re-treatment can be provided to thoroughly ablate the tumor below 5 cm. For the tumors with a diameter ≥ 2 cm, 17G single cryoprobe treatment is performed using the 2-to-1 principle. Thermal subsidence of large vessel should be considered for PC, which has a greater effect on the size and shape of isothermal field. If tumor is

adjacent to the vessel, the cryoprobe should be placed close to the vessel as precisely as possible. The ideal method is to place the cryoprobe within the tumor edge of vascular side about 0.5 cm and <1 cm to form a low-temperature field sufficiently. Some tests have proved that PC could not harm the vascular wall.²⁵ If the tumor is at the top or at a higher place of right lobe of the liver, it is necessary to perform intercostal puncture and pay attention to avoid hurting the pleural cavity; for the tumor at the top of the liver, CT guidance should be used to reduce the possibility of pneumothorax.

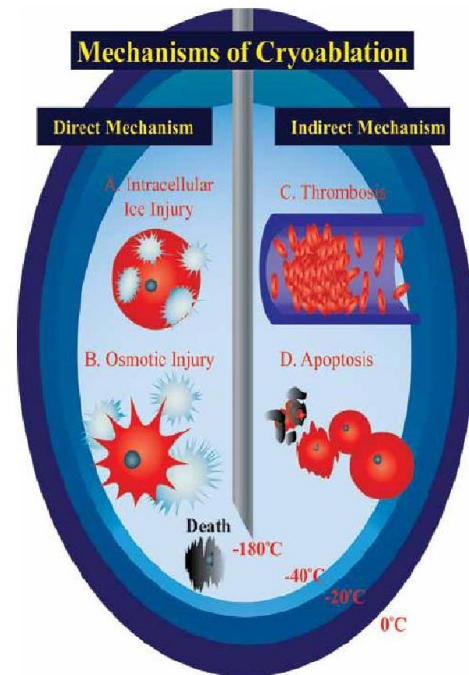


Figure 1. Mechanisms of Cryoablation A. The temperature of tissues adjacent to argon-helium knife drops sharply, resulting in cell death due to the formation of ice crystals inside the cell; B. The temperature of tissues a little far from argon-helium knife drops relatively slowly. Later ice crystals form outside the cell, resulting in the change in osmotic pressure and dehydration of cell rupture; C. Ischemia due to disrupted small vessel and thrombosis; D. Apoptosis.

Imaging Guidance

US, CT, or MRI guidance can be used in PC; of which MRI guidance is considered as the optimum. Ice ball on the MRI presents an evident low signal and is clearly visible. MRI has a better resolution of soft tissue than the CT, and can clearly exhibit tumor. Besides, MRI can investigate the tumor and ice ball at multiple planes to check whether the tumor is wrapped in the ice ball. Even then, most medical centers still choose US or CT guidance due to the constraints of equipment. The advantages of US guidance are that it has a better resolution of soft tissue and can supervise the location of tumor and formation of ice ball in real time. It shows that the leading edge of ice ball presents “arc-shaped” bright band and the back of ice ball presents “clean” acoustic shadow. Although US can clearly monitor the ice ball, the acoustic

shadow could affect the observation of deep tumors. On CT, the ice ball is identified as a low-density area around high-density cryoprobe and it has clear boundaries with peripheral tissues so that treatment could be supervised precisely. However, the main limitation of CT guidance is the low resolution of some tumors as well as the imprecise guidance due to the ambiguous identification against peripheral tissues, and it is difficult to distinguish soft tissues containing fat and ice ball, which may lead to incidental injury.

Cryoablation, Freezing, and Number of Times of Thaw

The size and shape of the ice ball are determined using the number of cryoprobe, distance from the cryoprobe, blood flow around the cryoprobe, and energy output. Generally, 100% energy output and two times of thermal-cold cycle (15 min per time) can sufficiently kill the tumors. The increase in the duration of cryoablation and number of times of thermal-cold cycle can enlarge the volume of ice ball to a limited extent. For the tumor edge that cannot be completely ablated after two times of thermal-cold cycle, it is difficult to make it fully ablated even if the third thermal-cold cycle is performed. In this case, a new cryoprobe should be placed or the placement of the previous cryoprobe should be adjusted.

Anesthetic Methods

Local or general anesthesia was provided depending on the design of cryotherapy used by the surgical physician. Pain caused by PC is less than the thermal ablation including RFA; however, local anesthesia method with auxiliary sedation is usually adopted. In case the tumor is located in a difficult-to-treat region or the patients need repeated treatments and can hardly expected to hold breath, general anesthesia is usually recommended.

Postoperative Management

Postoperative management mainly involves monitoring the vital signs and timely detection of relevant complications. After surgery, intravenous glucose was provided to supplement fluid and energy, sodium bicarbonate was provided to alkalize urine to prevent myoglobinuria, symptomatic treatment was provided for antiemesis and sedation, and patient-controlled intravenous analgesia was provided for the patients experiencing pain caused by the special location of the tumor.

SAFETY OF PC

PC is a type of minimally invasive technology. The incidence of complication varies due to some factors such as grade of liver function, diameter of the cryoprobe, location as well as area of the tumor, and duration of ablation. Some severe complications may occur due to the immature treatment experience. The incidence of complication in 300 patients with HCC at the hospital was 6.3%, involving six patients with cryoablation reaction syndrome, five patients with hepatorrhesis, four patients with stress gastrorrhagia with erosion, two patients with hepatic failure, one patient with liver abscess, and intestinal fistula.²⁶ Some innovative measures were established after the analysis: (1) PC was changed using cryoprobe guidance location, and hemostasis

was performed using hemostatic gel foam sponges, which was imported cryoprobe track through vascular; (2) the edge of complete ablation declined from 2 to 1 cm over tumor boundary, and warm brine and general electric blanket warmth were provided for cryoprobe zone. After the treatment, the occurrence of cryoablation reaction syndrome declined from 2 to 0.58%, and the rate of local recurrence did not increase; and (3) anhydrous alcohol injection combined with cryoablation or manual injection of sterile normal saline was used to isolate the intestine for the refractory lesions, and the rate of occurrence of serious complications after PC declined from 6.3 to 3.4%^{27,28} and had acceptable safety (Table 1). This measures have been popularized.

EFFICACY

In the early phase, the study found that the US guidance of PC can thoroughly ablate the focus of the tumor to less than 5 cm [35]. The duration of median follow-up was 37 months (8 to 48 months). The rates of survival at 1, 2, and 3 years were 92, 82, and 64%, respectively, and the disease-free survival rates at 1, 2, and 3 years were 72, 56, and 43%, respectively. Eight-five (54.5%) patients had relapse in 4 years. Even though PC has significantly improved the rate of survival of patients with HCC, the higher rate of recurrence is a demerit for further improvement in PC for patients with cirrhosis-related HCC. Therefore, alone US guidance location was replaced by both of CT and US bidirectional guidance location and timely monitoring. The patients with positive hepatitis B DNA virus were provided antiviral drug therapy of nucleoside for before PC. After the treatment, the long-time prognosis of 866 patients with cirrhosis-related HCC who met the Milan criteria of PC showed that the rate of complete ablation was up to 96.1%, and the duration of median survival for the patients with HCC after PC was up to 77.9 months. The rates of survival at 1, 3, and 5 years were 98.6, 80.6, and 60.3%, respectively, and the rates of local recurrence at 1, 3, and 5 years were 10.7, 22.1, and 24.3%, respectively. The positive clinical effect was similar to the long-term prognosis of RFA for HCC in recent studies (Table 2). A randomized clinical trial (RCT) that compared the PC and RFA for the lesions with 4 cm diameter of HCC²⁸ showed that rates of the complete ablation were 98.3 and 95.65%, respectively, and the control rates of local tumor were 5.6 and 10%, respectively ($P=0.126$, $P=0.115$). When the diameter of the tumor was >3 cm, the control rate of local tumor of PC was superior to RFA (7.7 vs 18.2%; $P=0.041$). The potential superiority of PC was shown by the RCT study for the first time, as per the result of non-RCTs.^{39,40} Hence, not only PC kills tumor directly, but also it confirms the selective cryoablation for advanced HCC resulted with ectopic anti-tumor effect that can inhibit tumor with the potential Cryo-immunology. In total, 120 patients with advanced HCC were analyzed prospectively and retrospectively, and the duration of median follow-up was 9 months. The clinical results showed that the duration of median survival was 10.5 months in the advanced HCC after PC and the median time to progress was 5.5 months. The rate of clinical effectiveness was 16.7%, the rate of disease control was up to 62.5%, the rate of ectopic anti-tumor effect

was 6%, and the rate of incidence of severe complications was merely 6.3%. The study proposed that after PC, the

reduced PD-1/PD-L1 and regulatory T-cells were closely associated with ectopic anti-tumor effect.^{42,43}

Table 1. Incidence of complications on percutaneous cryoablation for hepatocellular carcinoma at different stages.

| Authors Year | Journal Volume, Page | Study Design | Number | Severe implication (%) | Bleeding (%) | CS (%) | L A (%) | Cryoshock (%) | LI (%) | B or BF (%) | Seeding (%) |
|-----------------------------------|--|---------------|--------|------------------------|--------------|--------|---------|---------------|--------|-------------|----------------------|
| Joachim K. S 1999 ²⁹ | World J Surg. 23(2):109-14 | Retrospective | 2173 | 48.3 | 12 | 8.3 | 9 | 1 | 12 | 6 | - |
| Pearson et al. 1999 ³⁰ | Am J Surg. 178:592-99 | Prospective | 54 | 40.7 | 3.7 | 5.8 | 22.2 | 2 | 7 | - | - |
| Tait et al. 2002 ³¹ | Br J Surg. 89:1613-19 | Prospective | 44 | 43.2 | 34.1 | 4.5 | - | - | 4.5 | - | - |
| Bilchik et al. 2000 ³² | Arch Surg. 135:657-64 | Prospective | 159 | 23.0 | 11.8 | 3.6 | 7.0 | - | - | 4 | - |
| Yang et al. 2012 ²⁶ | J Hepatobiliary Pancreat Sci. 19:674-684 | Prospective | 300 | 6.3 | 2.0 | 2.0 | 0.33 | - | 0.67 | 0.33 | 0.76 ^[34] |
| Wang et al. 2014 ²⁸ | Hepatology. | RCT | 360 | 3.9 | 1.1 | 0.55 | - | - | 0.55 | - | - |
| Rong et al. 2015 ²⁷ | PLoS ONE. 10: e23621. | Prospective | 866 | 2.4 | 0.32 | 0.58 | 0.16 | - | 0.34 | 0.11 | 0.67 |
| Rong et al. 2015 ³³ | Front Med. 9(1):63-71 | Retrospective | 1595 | 3.4 | 0.38 | 1.08 | 0.17 | 0.06 | 0.52 | 0.04 | 0.9 |

RCT, randomized controlled trial; CS, cryoreaction syndrome; LA, liver abscess; LI, liver injury; B or BF, biliary or bowel fistula.

ISSUES AND PROSPECTS

In conclusion, PC is a potential local ablation technique and can effectively ablate larger lesions. Bleeding in the path of cryoprobe and implantation metastasis can be significantly reduced by hemostatic technology and reasonable puncture path. Using the guidance of US or CT, no absolute contraindication to PC was found if the puncture path can be kept away from the adjacent vessel, blood vessel, and gastrointestinal gall bladder. Whereas, the liver function of patient and overall rate of survival should be considered. Many issues should be studied further: (1) evaluation of image (CT or MRI) and dynamic change in the duration of follow-up after PC; (2) some studies have reported that the growth of residual tumors could be stimulated after RFA, but whether uncompleted cryotherapy would stimulate the growth of residual tumors still need to be analyzed; and (3) immunity due to cryosurgery.

CONFLICT OF INTEREST

The authors declare no competing financial interests.

GRANT SUPPORT

This work was supported by the Military Special-Purpose Program (No. BWS11J074) and the Chinese National Science Fund (No. 81272330).

DISCLOSURES

The authors disclose no conflicts.

REFERENCES

- European Association for the Study of the Liver; European Organisation for research and Treatment of Cancer. EASL-EORTC clinical practice guidelines: management of hepatocellular carcinoma. *J Hepatol.* 2012;56:908-943.
- Babaian RJ, Donnelly B, Bahn D, et al. Best practice statement on cryosurgery for the treatment of localized prostate cancer. *J Urol.* 2008;180:1993-2004.
- Rubinsky B. Cryosurgery. *Annu Rev Biomed Eng.* 2000;2:157-187.
- Erinjeri JP, Clark TW. Cryoablation: mechanism of action and devices. *J Vasc Interv Radiol.* 2010;21(8 Suppl):S187-S191.
- Baust JG, Gage AA. The molecular basis of cryosurgery. *BJU Int.* 2005;95:1187-1191.
- Rupp CC, Hoffmann NE, Schmidlin FR, et al. Cryosurgical changes in the porcine kidney: histologic analysis with thermal history correlation. *Cryobiology.* 2002;45(2):167-182.
- Kimura M, Rabbani Z, Mouraviev V, et al. Morphology of hypoxia following cryoablation in a prostate cancer murine model: its relationship to necrosis, apoptosis and, microvessel density. *Cryobiology.* 2010;619:148-154.
- Yang WL, Addona T, Nair DG, et al. Apoptosis induced by cryoinjury in human colorectal cancer cells is associated with mitochondrial dysfunction. *Int J Cancer.* 2003;103:360-369.
- Baust JG, Gage AA, Clarke D, et al. Cryosurgery -- a putative approach to molecular-based optimization. *Cryobiology.* 2004;48:190-204.
- Klossner DP, Baust JM, VanBuskirk RG, et al. Cryoablative response of prostate cancer cells is influenced by androgen receptor expression. *BJU Int.* 2008;101:1310-1316.
- Clarke DM, Robilotto AT, VanBuskirk RG, et al. Targeted induction of apoptosis via TRAIL and cryoablation: a novel strategy for the treatment of prostate cancer. *Prostate Cancer Prostatic Dis.* 2007; 10:175-184.
- Weber S, Lee F. Cryoablation: History, Mechanism of Action, and Guidance Modalities. New York: Springer, 2005:250-265.
- Clarke DM, Robilotto AT, Rhee E, et al. Cryoablation of renal cancer: variables involved in freezing-induced cell death. *Technol Cancer Res Treat.* 2007;6(2):69-79.
- Woolley ML, Schulsinger DA, Durand DB, et al. Effect of freezing parameters (freeze cycle and thaw process) on tissue destruction following renal cryoablation. *J Endourol.* 2002;16:519-522.
- Maccini M, Seht D, Pompeo A, et al. Biophysiological considerations in cryoablation: a practical mechanistic molecular review. *Int Braz J Urol.* 2011;37:693-696.
- Liu Z, Ahmed M, Weinstein Y, et al. Characterization of the RF ablation-induced 'oven effect': the importance of background tissue thermal conductivity on tissue heating. *Int J Hyperthermia.* 2006; 22:327-342.
- Orlacchio A, Bazzocchi G, Pastorelli D, et al. Percutaneous cryoablation of small hepatocellular carcinoma with US guidance and

- CT monitoring: initial experience. *Cardiovasc Intervent Radiol.* 2008;31:587-594.
18. Shimizu T, Sakuhara Y, Abo D, et al. Outcome of MR –guided percutaneous cryoablation for hepatocellular carcinoma. *J Hepatobiliary Pancreat Surg.* 2009;16:816-823.
 19. Weber SM, Lee FT Jr, Warner TF, et al. Hepatic cryoablation: US monitoring of extent of necrosis in normal pig liver. *Radiology.* 1998;207:73-77.
 20. Callstrom MR, Charboneau JW. Technologies for ablation of hepatocellular carcinoma. *Gastroenterology.* 2008;134:1831-1835.
 21. Allaf ME, Varkarakis IM, Bhayani SB, et al. Pain control requirements for percutaneous ablation of renal tumors: cryoablation versus radiofrequency ablation-initial observations. *Radiology.* 2005;237:366-370.
 22. Shock SA, Laeseke PF, Sampson LA, et al. Hepatic hemorrhage caused by percutaneous tumor ablation: radiofrequency ablation versus cryoablation in a porcine model. *Radiology.* 2005;236:125-131.
 23. Wang H, Litttrup PJ, Duan Y, et al. Thoracic masses treated with percutaneous cryotherapy: initial experience with more than 200 procedures. *Radiology.* 2005;235:289-298.
 24. Hinshaw JL, Lee FT Jr. Cryoablation for liver cancer. *Tech Vasc Interv Radiol.* 2007;10:47-57.
 25. Müller-Schweinitzer E. Arterial smooth muscle function after prolonged exposure to a medium containing dimethyl sulfoxide (Me₂SO) and storage at -196 degrees C. *Cryobiology.* 1994;31:330-335.
 26. Yang YP, Wang CP, Lu YY, et al. Outcomes of ultrasound-guided percutaneous argon- helium cryoablation of hepatocellular carcinoma. *J Hepatobiliary Pancreat Sci.* 2012;19:674-684.
 27. Rong GH, Bai WL, Dong Zheng, et al. Long-term Outcomes of Percutaneous Cryoablation for Patients with Hepatocellular Carcinoma within Milan Criteria. *PLOS ONE.* 2015;10:e23621.
 28. Wang C, Wang H, Yang W, et al. Multicenter Randomized Controlled Trial of Percutaneous Cryoablation Versus Radiofrequency Ablation Therapy in Patients with Hepatocellular Carcinoma. *Hepatology.* 2015;61:1579-1590.
 29. Joachim K, Seifert, MD, Morris DL. World Survey on the Complications of Hepatic and Prostate Cryotherapy. *World J Surg.* 1999;23(2):109-114.
 30. Pearson AS, Izzo F, Fleming RY, et al. Intraoperative radiofrequency ablation or cryoablation for hepatic malignancies. *Am J Surg.* 1999;178:592-599.
 31. Tait IS, Yong SM, Cuschieri SA. Laparoscopic in situ ablation of liver cancer with cryotherapy and radiofrequency ablation. *Br J Surg.* 2002;89:1613-1619.
 32. Bilchik AJ, Wood TF, Allegra D, et al. Cryosurgical ablation and radiofrequency ablation for unresectable hepatic malignant neoplasms: a proposed algorithm. *Arch Surg.* 2000;135:657-662;
 33. Rong G, Bai W, Dong Z, et al. Cryotherapy for cirrhosis-based hepatocellular carcinoma: a single center experience from 1595 treated cases. *Front Med.* 2015;9:63-71.
 34. Wang CP, Wang H, Qu JH, et al. Tumour seeding after percutaneous cryoablation for hepatocellular carcinoma. *World J Gastroenterol.* 2012;18:6587-6596.
 35. Wang C, Lu Y, Chen Y, et al. Prognostic factors and recurrence of hepatitis B -related hepatocellular carcinoma after argon –helium cryoablation: a prospective study. *Clin Exp Metastasis.* 2009;26:839-848.
 36. Kim YS, Lim HK, Rhim H, et al. Ten-year outcomes of percutaneous radiofrequency ablation as first-line therapy of early hepatocellular carcinoma: analysis of prognostic factors. *J Hepatol.* 2013;58:89-97.
 37. Rossi S, Ravetta V, Rosa L, et al. Repeated radiofrequency ablation for management of patients with cirrhosis with small hepatocellular carcinomas: A long-term cohort study. *Hepatology.* 2011;53:136-147.
 38. Shiina S, Tateishi R, Arano T, et al. Radiofrequency ablation for hepatocellular carcinoma: 10-year outcome and prognostic factors. *Am J Gastroenterol.* 2011;107:569-577.
 39. Dunne RM, Shyn PB, Sung JC, et al. Percutaneous treatment of hepatocellular carcinoma in patients with cirrhosis: A comparison of the safety of cryoablation and radiofrequency ablation. *Eur J Radiol.* 2014;83:632-638.
 40. Shigenori E, Taizo H, Minoru T, et al. Cryoablation Provides Superior Local Control of Primary Hepatocellular Carcinomas of > 2 cm Compared with Radiofrequency Ablation and Microwave Coagulation Therapy: An Underestimated Tool in the Toolbox. *Ann Surg Oncol.* 2015;22:1294-1300.
 41. Yang YP, Qu JH, Chang XJ, et al. High intratumoral metastasis-associated in colon cancer-1 expression predicts poor outcomes of cryoablation therapy for advanced hepatocellular carcinoma. *J Transl Med.* 2013;11:41-55.
 42. Zhou L, Fu JL, Lu YY, et al. Regulatory T cells are associated with post-cryoablation prognosis in patients with hepatitis B virus-related hepatocellular carcinoma. *J Gastroenterol.* 2010;45:968-978.
 43. Zeng Z, Shi F, Zhou L, et al. Upregulation of circulating PD-L1/PD-1 is associated with poor post-cryoablation prognosis in patients with HBV-related hepatocellular carcinoma. *PLOS ONE.* 2011;6:e23621.