

# The Pathology of Pemphigus: A Mini-Review

Christopher A. D'Angelis, MD, PhD\*

Department of Pathology, Veterans Affairs Medical Center, Buffalo, NY  
State University of New York at Buffalo, Buffalo, NY

**Pemphigus is a rare group of blistering autoimmune diseases that affect the skin and mucous membranes. Variants of pemphigus are now known to be associated with certain medications, underlying malignancy and even an endemic form is well recognized. Following the discovery of the autoimmune basis of pemphigus, specific treatment regimens have made strides in significantly reducing the morbidity and mortality once associated with the disease. Traditional histopathology and tissue based techniques have played a pivotal role in the understanding of pemphigus and in highlighting the diversity within this group of diseases. The examination of skin biopsies by light microscopy and immunofluorescence remains the standard for diagnosis today.**

[*N A J Med Sci.* 2013;6(1):37-40. DOI: 10.7156/najms.2013.0601037]

**Key Words:** *Pemphigus, histopathology, skin biopsies*

## INTRODUCTION

Pemphigus is comprised of a group of related auto-immune blistering dermatoses with a reported incidence of 0.76 to 5 new cases per million per year,<sup>1</sup> however, higher rates are reported in specific regions of the world, such as Brazil.<sup>2</sup> Although the variants within the pemphigus group share many clinical similarities, unique differences amongst them are well recognized, specifically with regards to their severity, anatomic distribution and precipitating factors. Initially, the diagnosis of pemphigus and its variants was based solely upon the evaluation of skin biopsies. With the advent of immunofluorescence techniques, the auto-immune basis of pemphigus was defined and currently direct immunofluorescence of skin biopsies is a common adjunct test to basic histopathology. More recently, the molecular basis of pemphigus has been described and with these new discoveries, many of the clinical variations within the pemphigus group have begun to be explained.

In the broadest sense, all entities within the pemphigus group produce blisters *within* the epidermis - this is in contrast to the pemphigoid group of diseases which produce blisters *beneath* the epidermis *i.e.*, at the level of the basement membrane adjoining the epidermis and dermis. The pemphigus group is traditionally further classified on histologic grounds according to the level of the epidermis affected. The prototype of the pemphigus group is pemphigus vulgaris (PV), in which blisters form within the deepest layers of the epidermis. The second pemphigus group includes entities causing blisters confined to the superficial epidermis, of which, pemphigus foliaceus (PF) is the most common. Generally, forms of pemphigus causing

blisters within the deep epidermis are associated with more widespread lesions and produce greater overall morbidity.

## CLINICAL PRESENTATION OF PEMPHIGUS

The clinical distinction between PV and PF has been recognized for quite some time.<sup>1,3</sup> Pemphigus vulgaris produces flaccid blisters which are often widespread and usually involve mucosal surfaces. In some cases of PV, mucosal blisters may be the only finding. The blisters of PV are fragile and easily rupture, leaving behind painful erosions which heal poorly. Large body surface area can be affected by PV, resulting in a severe loss of barrier function and profound morbidity. Before the advent of corticosteroid therapy, the mortality rate for PV was reportedly as high as 50%.<sup>4</sup> In contrast to PV, the clinical lesions of PF are often localized, most often to the head and upper trunk (so-called seborrheic distribution) and are not usually reported as painful. Mucosal lesions do not occur. Although PF is a blistering disease, clinical blisters are not apparent because of the extremely fragile superficial nature of the lesion (see histology section below). The characteristic PF lesions often present as crusted scaly erosions. The differing clinical manifestations between PV and PF result from their distinct histopathology.

## HISTOPATHOLOGY

The defining histopathologic feature of pemphigus is an intraepidermal blister formed by the process of acantholysis.<sup>5</sup> Acantholysis is the separation of keratinocytes due to a loss of the normal cell to cell attachments. As keratinocytes separate the clinical blister is formed. It is important to note that intra-epidermal blister formation is also a component of many other unrelated diseases. For example, acute eczematous dermatitis (which includes common conditions such as atopic and allergic contact dermatitis) is capable of

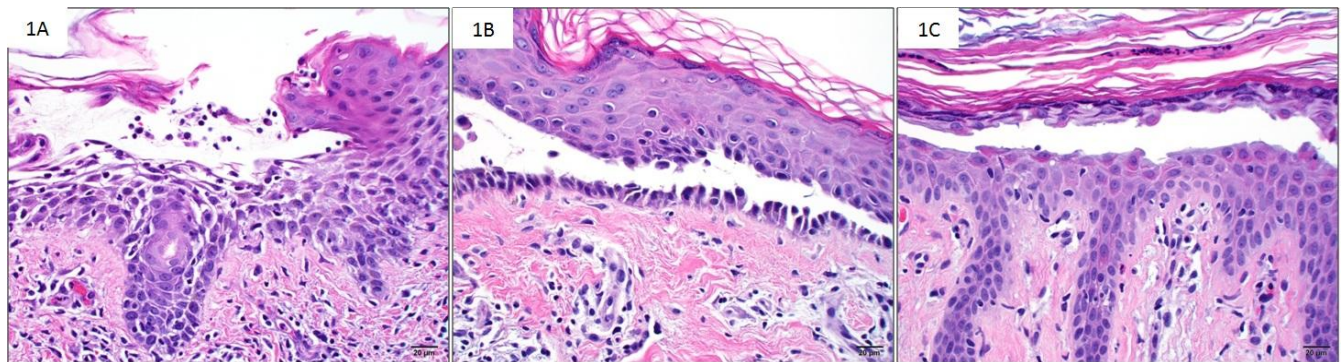
Received 12/26/2012; Revised 01/25/2013; Accepted 01/25/2013

\*Corresponding Author: Department of Pathology, VAMC, 3495 Bailey Ave, Buffalo, NY, 14215. Tel: 716-862-5739.

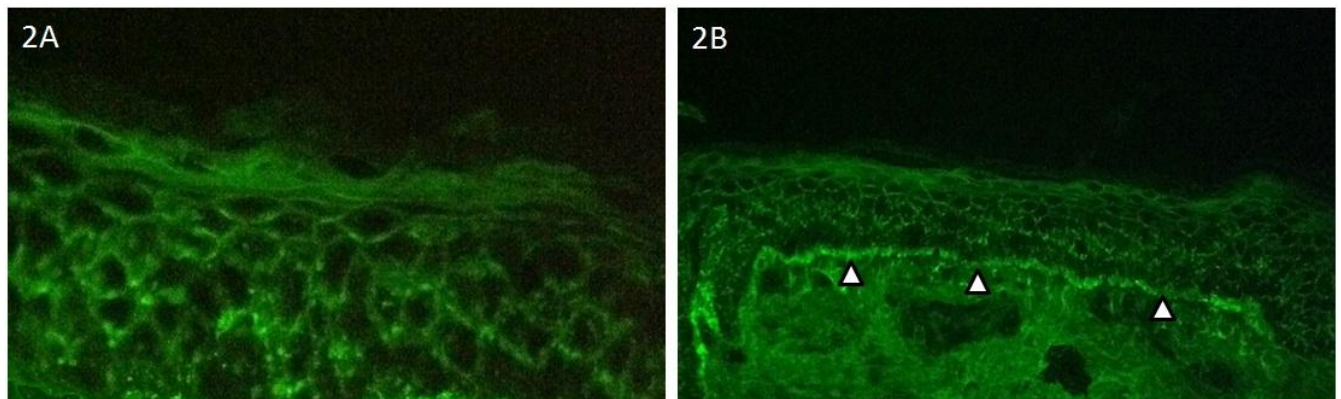
(Email: christopher.dangelis@va.gov)

producing blisters by the exudation of fluid between keratinocytes. This separation may mimic true acantholysis, however, upon closer inspection normal attachments between keratinocytes can be seen (**Figure 1A**). Of note, in its earliest stages, pemphigus may present histologically solely as spongiosis (similar to a mild eczematous dermatitis) often with an increased numbers of intraepithelial eosinophils or as very focal acantholysis involving only the epithelium of the hair follicle.<sup>5</sup> On histologic examination some of the fundamental differences between PV and PF become apparent. In PV the separation of keratinocytes occurs in the lowest portion of the epidermis, usually seen as space

between the basal cells (those attached to the basement membrane) and the cells above. This process produces a characteristic histologic pattern often referred to tombstones, as basal keratinocytes project into the blister cavity (**Figure 1B**). In contrast, the histologic blister produced by PF is most often seen as a split between the most superficial keratinocytes, usually with the granular layer of the epidermis, just beneath the stratum corneum (**Figure 1C**). These superficial skin cells can often be seen clinging to the blister wall. In both PV and PF the surrounding inflammation is minimal.



**Figure 1.** The histopathology of pemphigus. Blister formation in spongiotic (eczematous) dermatitis shows separation of keratinocytes (**A**). At higher power, retained cellular bridges can be seen (inset). Pemphigus vulgaris showing acantholysis just above the basal keratinocytes (**B**). Pemphigus foliaceus demonstrating characteristic superficial acantholysis (**C**).



**Figure 2.** Direct immunofluorescence of pemphigus. Binding of pathologic IgG is demonstrated using fluorescein-labeled anti-IgG probes – producing a fishnet pattern of staining in PV (**A**). The pemphigus variant, pemphigus erythematosus showing both intercellular and basement membrane staining (arrows) for IgG (**B**).

## IMMUNOPATHOLOGY

The evidence for the autoimmune nature of pemphigus was first advanced by the demonstration of serum from PV patients binding to the epidermis of normal skin samples.<sup>6</sup> Using immunofluorescence techniques the presence of antibodies bound *in vivo* to keratinocytes of pemphigus patients was further demonstrated.<sup>7</sup> Currently, similar techniques are commonly applied in diagnostic practice by the incubation of frozen section skin biopsies with fluorescein-labeled anti-immunoglobulin antibodies (termed

direct immunofluorescence (DIF) testing). The binding of these fluorescent-labeled antibody probes to the pathogenic immunoglobulins within the epidermis produces a pattern of staining characteristic of pemphigus. Specifically, the deposition of fluorescence labeling occurs between keratinocytes, producing a so-called fishnet pattern (**Figure 2A**). In contrast to other auto-immune dermatoses, such as lupus and pemphigoid basement membrane staining in pemphigus is absent, however, some specific pemphigus variants can produce mixed patterns of immunofluorescence.

One such condition is the pemphigus variant, pemphigus erythematosus, which demonstrates the characteristic immunofluorescence pattern of pemphigus along with deposition of IgG at the basement membrane (**Figure 2B**), similar to that seen in lupus.<sup>8</sup> Combined Immunofluorescence staining between keratinocytes and at the basement membrane is also seen in the pemphigus variant occurring in association with neoplasia (usually hematologic malignancies) – termed paraneoplastic pemphigus.<sup>9</sup> The pathogenic antibody in all variants of pemphigus is IgG with the exception of a variant caused by IgA (IgA pemphigus).<sup>9</sup> In normal skin, binding of anti-immunoglobulin probes within the epidermis and basement membrane should be completely absent however in chronically sun-exposed skin non-specific binding to the basement membrane area can be seen.<sup>10</sup>

### MOLECULAR PATHOLOGY

The basic unit that mediates cell to cell adherence between keratinocytes is the desmosome.<sup>11</sup> The desmosome is formed by the intercellular interaction between transmembrane proteins which are in turn anchored to intracellular proteins and cytoskeletal keratins. These transmembrane molecules are members of the cadherin family of proteins, termed desmosomal cadherins and consist of desmocollins and desmogleins. Currently there are three recognized isoforms of the desmocollins and the desmogleins.<sup>12</sup> The extracellular portion of the desmosome is formed from the binding of paired desmogleins and desmocollins between neighboring keratinocytes. The intracellular portion of the desmosome is formed from a complex consisting of plakoglobin (which binds desmoglein directly), plakophilin and desmoplakin, which anchors the desmosome to the keratin cytoskeleton. Multiple lines of experimental data have demonstrated that antibodies derived from PV patients specifically bind the 130kDa protein desmoglein-isotype-3 (dsg3) and antibodies from PF specifically bind the 160kDa protein desmoglein-isotype-1 (dsg1).<sup>13,14</sup> The exact mechanism by which antibody binding to dsg1 and dsg3 disrupts cell-cell binding is still unclear, however studies have demonstrated that antibody transfusion alone into neonatal mice and even passive transfer from mother to fetus across the placenta are capable of producing blisters.<sup>15,16</sup> Interestingly, it is now known that there is a specific differential distribution of dsg1 and dsg3 expression: first, related to their expression within the epidermis and second, with regards to anatomic site. It is this differential distribution of dsg1 and dsg3 expression that is responsible for the unique clinical manifestations of PV and PF.<sup>17</sup> The PF antigen, dsg1 is predominately expressed between superficial keratinocytes, thus explaining the shallow blister formation characteristic of PF. In contrast, the PV antigen, dsg3 is expressed predominately between cells of the deep, immediate supra-basilar region of the epidermis thus leading to the relatively deeper blister formation of PV. Additionally, mucosal sites have been shown to express significantly higher levels of dsg3 relative to dsg1, explaining the occurrence of mucosal blisters unique to PV.<sup>18</sup> Of note, it is now known that PV patients with both skin and mucosal blisters demonstrate *both* anti-dsg1 and anti-dsg3 and those with mucosal blisters only show anti-

dsg3.<sup>18</sup> These PV phenotypes are thought to occur because the intact dsg1 in PV can compensate for the loss of dsg3 function only in the skin and not in mucosa. In comparison, loss of dsg1 function alone as seen in PF, always results in skin blister formation as the remaining normal dsg3 cannot compensate. In PF, mucosal surfaces are spared due to their low level of dsg1 expression in comparison to dsg3.

A recently recognized variant, paraneoplastic pemphigus produces PV-like blisters usually with extensive mucosal involvement. Although most commonly seen in the setting of hematologic malignancies, paraneoplastic pemphigus has been reported in association with wide array of carcinomas and sarcomas.<sup>10</sup> Pathologic diagnosis of paraneoplastic pemphigus can be challenging as the histology is variable and often presents as a band-like infiltration of inflammatory cells, closely mimicking interface dermatoses such as erythema multiforme and lichen planus. Good clinical correlation along with tissue for immunofluorescence is essential in these cases. Immunoprecipitation techniques using sera from patients with paraneoplastic pemphigus have demonstrated autoantibodies directed against multiple different desmosomal proteins. To date, at least 8 distinct protein antigens have been associated with paraneoplastic pemphigus, including dsg1, dsg3, the desmoplakins, and the bullous pemphigoid antigen-1.<sup>19</sup> Although the cause of paraneoplastic pemphigus is unknown, current theories include aberrant expression of desmosomal-like proteins by tumor cells and immune dysfunction in the setting of hematologic malignancies.<sup>10</sup> Auto-IgA antibodies targeted to the other transmembrane proteins of the desmosome, the desmocollins are now known to be the cause of the pemphigus variant IgA pemphigus. The clinical and histologic lesions of IgA pemphigus are unique amongst the pemphigus group, producing pustules in addition to the characteristic pauci-inflammatory blister.<sup>5</sup>

Histopathologic and molecular-based techniques have contributed greatly to the understanding of the pathogenesis of pemphigus. The underlying immune-mediated mechanisms behind pemphigus however remain obscure and most likely represent a diverse group of stimuli capable of producing a similar clinical phenotype and histopathology. Variants of pemphigus are now known to be associated with certain medications (e.g. penicillamine),<sup>20</sup> underlying malignancy and even an endemic form is well recognized.<sup>21</sup> Following the discovery of the autoimmune basis of pemphigus, specific treatment regimens have made strides in significantly reducing the morbidity and mortality once associated with the disease. Traditional histopathology and tissue based techniques have played a pivotal role in the understanding of pemphigus and in highlighting the diversity within this group of diseases. The examination of skin biopsies by light microscopy and immunofluorescence remains the standard for diagnosis today.

---

### CONFLICT OF INTEREST

The author has no conflicts of interest to disclose.

---

### REFERENCES

1. Masayuki A. Pemphigus. In: Bologna, JL, Jorizzo, JL, Rapini, RP, eds. *Dermatology* 2<sup>nd</sup> Edition. New York: Mosby: 2008:417-429.



2. Warren SJ, Lin MS, Giudice GJ, et al. The prevalence of antibodies against desmoglein 1 in endemic pemphigus foliaceus in Brazil. *N Engl J Med.* 2000;343(1):23-30.
3. Guillen S, Khachemoune A. Pemphigus vulgaris: a short review for the practitioner. *Dermatol Nurs.* 2007;19(3):269-272.
4. Anhalt GJ, Diaz LA. Pemphigus vulgaris – a model for cutaneous autoimmunity. *J of Am Acad of Dermatol.* 2004;51(1 Suppl):S20-1.
5. Weedon D. The vesicobullous reaction pattern. In: Weedon D. *Skin Pathology 3<sup>rd</sup> Edition.* New York: Elsevier; 2010:123-168
6. Beutner EH, Jordon RE. Demonstration of skin antibodies in sera of pemphigus vulgaris patients by indirect immunofluorescent staining. *Exp Biol Med.* 1964;117(2):505-510.
7. Jordon RE, Triftshouser CT, Schroeter AL. Direct immunofluorescent studies of pemphigus and bullous pemphigoid. *Arch. Derm.* 1971;103(5):486-491.
8. Maize JC, Freen D, Provost TT. Pemphigus foliaceus: a case with serologic features of Seneur-Usher syndrome and other autoimmune abnormalities. *J Am Acad Dermatol.* 1982;7(6):736-741.
9. Reich A, Marcinow K, Bialynicki-Birula R. The lupus band test in systemic lupus erythematosus patients. *Ther Clin Risk Manag.* 2011;7:27-32.
10. Robinson ND, Hashimoto T, Amagai M, et al. The new pemphigus variants. *J Am Acad Dermatol.* 1999;40(5):649-671.
11. Garrod D, Chidgey M. Desmosome structure, composition and function. *Biochem Biophys Acta.* 2008;1778(3):572-587.
12. Denning MF, Guy SG, Ellerbroek SM, et al. The expression of demoglein isoforms in cultured human keratinocytes is regulated by calcium, serum and protein kinase C. *Exp Cell Res.* 1998;239(1):50-59.
13. Stanley JR, Koulo L, Thivolet C. Distinction between epidermal antigens binding pemphigus vulgaris and pemphigus foliaceus autoantibodies. *J Clin Invest.* 1984;74(2):313-320.
14. Amagai M, Klaus-Kovtun V, Stanley JR. Autoantibodies against a novel epithelial cadherin in pemphigus vulgaris, a disease of cell adhesion. *Cell.* 1991;67(5):869-877.
15. Merlob P, Metzker A, Hazaz B et al. Neonatal pemphigus vulgaris. *Pediatrics.* 1986;78(6):1102-1105.
16. Anhalt GJ, Labib RS, Voorhees JJ, et al. Induction of pemphigus in neonatal mice by passive transfer of IgG from patients with the disease. *N Engl J Med.* 1982;306(20):1189-1196.
17. Amagai M, Tsunoda K, Zillikens D, et al. The clinical phenotype of pemphigus is defined by the anti-desmoglein autoantibody profile. *J Am Acad Dermatol.* 1999;40(2):167-170.
18. Mahoney MG, Wang Z, Rothenberger K, et al. Explanation for the clinical and microscopic localization of lesions in pemphigus foliaceus and vulgaris. *J Clin Invest.* 1999;103(4):461-468.
19. Anhalt GJ, Kim SC, Stanley JR, et al. Paraneoplastic pemphigus. An autoimmune mucocutaneous disease associated with neoplasia. *N Engl J Med.* 1990;323(25):1729-1735.
20. Ho VC, Stein HB, Ongley RA, et al. Penicillamine induced pemphigus. *J of Rheumatol.* 1985;12(3):583-586.
21. Diaz LA, Sampaio S, Rivitti EA, et al. Endemic pemphigus foliaceus (fogo selvagem): Current and historical epidemiological aspects. *J Invest Dermatol.* 1989;92(1):4-12.