

**Case Report**

# A Rare Case of Mediastinitis Following a Routine Dental Procedure in a Patient with History of Cardiac Surgery

Charles DeMesa, DO;<sup>1</sup> Xixi Amley, MD;<sup>2\*</sup> Pang Lam, MD;<sup>1</sup>  
Maxine Seales, MD;<sup>1</sup> Joshua Kerstein, MD;<sup>2</sup> Jacob Shani, MD<sup>2</sup>

<sup>1</sup> Department of Medicine Maimonides Medical Center, Brooklyn, New York

<sup>2</sup> Department of Cardiology Maimonides Medical Center, Brooklyn, New York

**Mediastinitis is a rare, severe condition associated with increased morbidity and mortality. Mediastinitis, a life-threatening infection, may occur during the postoperative period following cardiovascular surgery. We present a unique case of mediastinitis following a dental procedure in a 47 year old healthy male with a past surgical history of acute type 1 aortic dissection repaired with Dacron tube graft and re-suspension of his aortic valve, 16 months earlier. He was noted to have induration on his right pectoralis muscle and underwent chest Computerized Tomography (CT) scan revealing infectious mediastinitis. His condition improved after CT-guided abscess aspiration and a six-week course of intravenous antibiotics. Mediastinitis may result from an infection extending from the oropharynx inferiorly through deep spaces of the neck as a descending necrotizing mediastinitis. This case suggests that disruption of fascial planes following cardiac surgery may predispose individuals to acquire anterior mediastinitis via a descending pathway long after completion of surgery.**

[N A J Med Sci. 2011;4(4):245-248.]

**Key Words:** *descending mediastinitis, post cardio-vascular surgery*

## INTRODUCTION

In the United States, most cases of mediastinitis result from intraoperative wound contamination as a complication of cardiothoracic surgery.<sup>1,2</sup> Other causes occur after esophageal perforation or from infections spread from odontogenic and/or retropharyngeal origins.<sup>3,4</sup> The potential spaces and deep spaces of the head and neck that may allow infections to enter the mediastinum include the carotid, submandibular, parapharyngeal, retropharyngeal, and danger spaces. An estimated 70% of cases of descending necrotizing mediastinitis occur in the danger space. Less commonly, infection may course inferiorly via the carotid space into anterior mediastinum.<sup>5</sup>

Rare causes of mediastinitis develop as a result of penetrating or blunt trauma, hematogenous spread of infection, and chronic fibrosing mediastinitis due to granulomatous infection.<sup>6,7</sup> The more common causes of mediastinitis with relevance to our case include postoperative mediastinitis following cardiovascular surgery and descending mediastinitis.

## CASE REPORT

The patient is a 47-year-old man who presented with complaints of tightness and pain in his right upper chest

radiating to his right shoulder and neck. He is a businessman in excellent physical shape, weight training six days per week and bicycling 30 miles at a time. He had no significant past medical or surgical history except for underlying hypertension diagnosed 2.5 years prior to this presentation. He had no medical therapy. While exercising the patient described a sensation of a "sudden pop" within his chest, which was severe, lasting few minutes and spontaneously resolved. He was seen by his cardiologist the following week. On physical exam, blood pressure was 140/90 mmHg with remainder of the exam unremarkable except for new onset 4/6 diastolic murmur at the left sternal border. A 12-lead EKG indicated normal sinus rhythm and echocardiogram revealed a proximal aortic dissection with severe aortic insufficiency subsequently confirmed on CT scan. Angiogram was not performed due to risk of advancement of the dissection. The patient underwent surgery to repair type I aortic dissection with re-suspension of the aortic valve. He recovered and was discharged. However on postoperative day 14, he had a syncope episode associated with urinary incontinence. He was hospitalized and diagnosed with atrial fibrillation with a heart rate of 130 beats per minute (BPM) from baseline of 40 BPM. Amiodarone corrected his atrial fibrillation. Eight months later, a follow-up nuclear stress test was completed with normal results. Six months afterwards, he noticed his heart rate was increasing disproportionately to his baseline and was diagnosed with hyperactive thyroiditis.

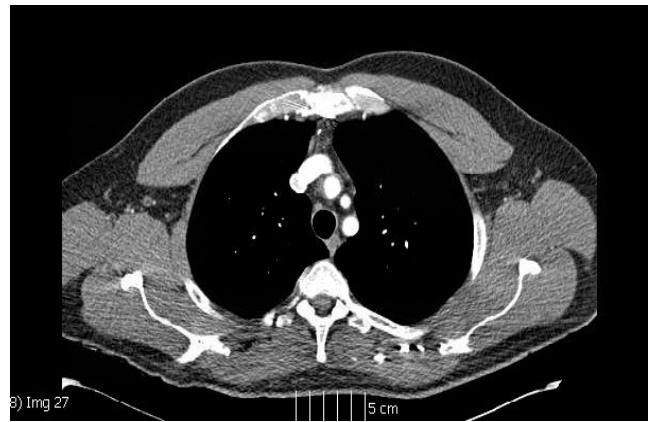
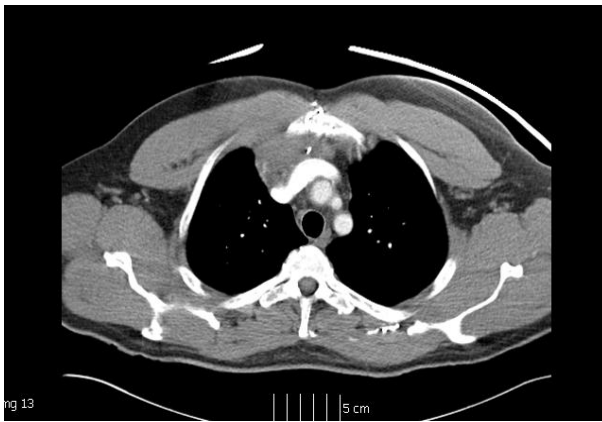Received 8/2/2011; Revised 8/30/2011; Accepted 9/2/2011

\*Corresponding Author: Maimonides Medical Center, Department of Cardiology, 4<sup>th</sup> floor, 4802 Tenth Avenue, Brooklyn, NY 11219-2999. (Email: xamley@maimonidesmed.org)

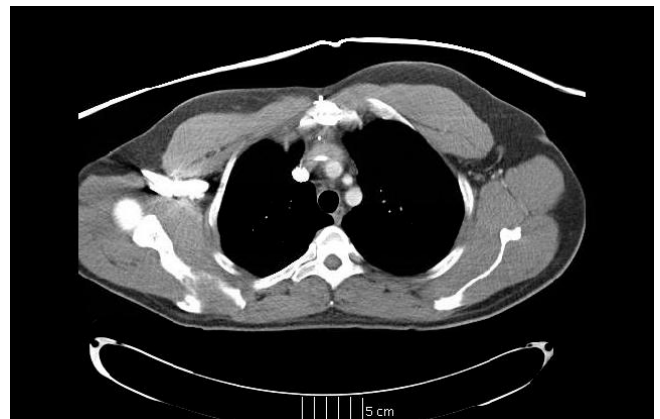
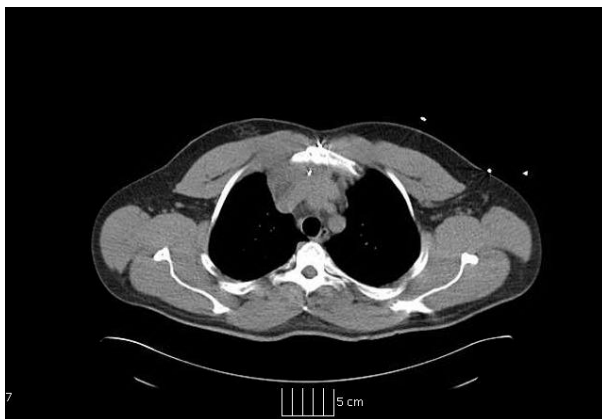Amiodarone was discontinued with improvement in his thyroid function tests.

Sixteen months post the aortic surgery, he began experiencing fatigue, generalized malaise, and fever of 102 Fahrenheit treated with acetaminophen. He quickly defervesced, but felt weak over several days and developed right shoulder/chest pain. Azithromycin and ibuprofen were prescribed and he was referred to a pain management physician who added acetaminophen with hydrocodone after cervical spine MRI showed disc herniation. Medication was changed to levofloxacin and oxycodone one day later. The next week, his cardiologist determined that his pain was

unlikely related to cervical radiculopathy because physical exam demonstrated asymmetry of his chest wall with right-sided prominence. CT scan revealed infectious mediastinitis with adjacent soft tissue swelling of the right pectoralis major and minor muscles (**Figure 1**). After abscess aspiration and antibiotic therapy, his condition improved. Repeat CT scan revealed resolution of the soft tissue swelling after antibiotic treatment (**Figure 2**). Blood cultures revealed *Methicillin Sensitive Staphylococcus aureus* (MSSA). On further investigation, he admitted to routine uncomplicated dental procedure two weeks prior to his febrile illness. Of note, he did take subacute bacterial endocarditis prophylaxis with Amoxicillin prior to the dental procedure.



**Figure 1.** 47 year-old man with mediastinitis likely secondary to Methicillin Sensitive *Staphylococcus aureus* at the level of the left innominate vein. Soft tissue fullness measuring 3.7 cm x 5.4 cm with adjacent soft tissue swelling of the right pectoralis major and minor muscles (left). CT image 2-months prior without any evidence of pathology (right).



**Figure 2.** CT guided aspiration of the anterior mediastinum using 10 cm 5 Fr. Yueh needle (left). Near complete resolution of the previously visualized soft tissue fullness within the anterior mediastinum, abutting the sternum (right).

## DISCUSSION

This case report describes an unexpected variation in the mediastinitis disease process. Two-thirds of patients with post-operative mediastinitis following cardiovascular surgery

present within a 14-day period.<sup>1</sup> Risk factors for the development of mediastinitis include emergency surgery, the use of pedicle bilateral internal mammary artery grafts after Coronary Artery Bypass Graft (CABG) (especially in

diabetic patients), obesity, chronic obstructive pulmonary disease, prolonged bypass/operating room time, and re-operation.<sup>8,9</sup> The cardiovascular surgical procedures that may result in postoperative mediastinitis include CABG, valve replacement/repair procedures, atrial septal defect closure, and heart transplant. The most important factor in pathogenesis of postoperative mediastinitis is intraoperative wound contamination. Many patients have multiple risk factors including a history of smoking, obesity, advanced age, and longstanding hypertension. This case describes an otherwise healthy individual with recent diagnosis of hypertension who underwent aortic dissection and valve repair without acute presentation of postoperative mediastinitis. He showed no evidence of wound contamination or complications during his recovery. Furthermore, there was no CT evidence suggestive of deep wound infection, enhancing soft tissue mass or collection, sternal dehiscence or erosion at that time. Hypopharynx or esophageal perforation secondary to intubation is another mechanism of developing mediastinitis. However, it has an acute presentation and progression with signs of sepsis or cardiovascular compromise post-intubation. Neither was this apparent. His mediastinitis occurred two weeks following a routine uncomplicated dental procedure. Although exceedingly rare, particularly with antibiotic prophylaxis, the etiology of his mediastinitis might have occurred by odontogenic descending infection via the carotid space into the anterior mediastinum. The vulnerability and alteration in fascial planes due to previous cardiac surgery may have created a nidus for infection preventing effective antibiotic penetration. There have been other cases reporting descending mediastinitis following dental procedures. One such reported case involved a descending necrotizing mediastinitis following dental implant surgery, but the previous health condition of that individual is unknown.<sup>10</sup> This report provides evidence that disruption of fascial planes following cardiac surgery may predispose otherwise healthy individuals to acquire anterior mediastinitis via a descending pathway, more than one and a half years after surgery.

Descending necrotizing mediastinitis is another cause of infectious spread. This is the most lethal form of mediastinitis, partly due to delayed diagnosis and treatment. Odontogenic infection is the most common cause.<sup>11</sup> The potential spaces and deep spaces of the head and neck that may allow infections to enter the mediastinum include the carotid, submandibular, parapharyngeal, retropharyngeal, and danger space. An estimated 70% of cases of descending necrotizing mediastinitis occur in the danger space.<sup>12</sup> This space is posterior to the retropharyngeal space. The danger space consists of two layers of fascia that are separated by loose connective tissue. The more anterior layer is the alar fascia and posterior layer is prevertebral fascia. The danger space may remain patent from connections located superiorly at the base of the skull as it courses inferiorly to the diaphragm located in the posterior mediastinum where its fascial layers combine. Because the retropharyngeal space is adjacent to the danger space, it provides a significant anatomic passage way for contiguous infectious spread from the neck into the mediastinum. For example, a mandibular

abscess may involve the submandibular space and infection may spread directly into the pharyngeal space continuing to the retropharyngeal space with extension into the danger space proceeding inferiorly to the mediastinum, causing mediastinitis. If the infection is due to polymicrobial gas-producing organisms then it would be deemed necrotizing.<sup>13,14</sup> Therefore, a descending necrotizing mediastinitis would develop. Less commonly, mediastinitis may course inferiorly via the carotid space within the carotid sheath into the anterior mediastinum. This pathway has been called "Lincoln's Highway."

A majority of patients have monobacterial infections, with isolation of Gram-positive cocci like *Staphylococcus aureus* and *Staphylococcus epidermidis* accounting for 70% to 80% of cases.<sup>15-17</sup> Mixed Gram-positive and Gram-negative infections account for approximately 40% of the cases while isolated Gram-negative infections are rare causes.<sup>16</sup> It must be noted that use of amoxicillin clavulanic acid followed by azithromycin and subsequently levofloxacin for treatment of flu-like symptoms and fever may have masked the typical presentation of a descending type mediastinitis. The use of multiple antibiotics may have blunted and delayed the onset of the classic manifestations of mediastinitis including high fevers, systemic toxicity, and local sign of erythema, edema, and fluctuance of the chest or neck. While the use of pain medications may have provided symptomatic relief, they too may have masked initial signs of infection at the site of mediastinitis. Clinical acumen and knowledge of the patient's history as well as skillful physical examination remain important factors in identifying these infections because they often have a rapid onset and progress to life-threatening complications.

Methicillin-sensitive *Staphylococcus aureus* isolated in this patient and this microorganism constitutes a small but significant number of cases of potential mediastinitis along with facultative Gram-negative organisms like *Pseudomonas aeruginosa*. These microorganisms tend to be more commonly isolated in immunocompromised individuals. The patient exhibited cold symptoms including high fever, fatigue and malaise prior to mediastinitis infection.

It must be noted that anaerobic bacteria more likely would be involved in most deep neck space infections extending to the mediastinum. For example, *Actinomyces israelii* is abundant on dental plaque and is frequently present in odontogenic infections and less commonly other *Actinomyces* species as well as *Arachnia propionica*. In contrast to bacteria of odontogenic origin, infections arising from the pharynx such as peritonsillar abscesses, contain all other anaerobes like *Fusobacterium necrophorum* and facultative *Streptococcus pyogenes*.

## CONCLUSION

Mediastinitis is a life-threatening infection which may occur during the postoperative period following cardiovascular surgery. It may also result from an infection extending from the oropharynx inferiorly through deep spaces of the neck as a descending necrotizing mediastinitis. This case report

describes an unexpected mediastinitis following a routine dental procedure. It suggests that disruption of fascial planes following cardiac surgery may predispose individuals to acquire anterior mediastinitis via a descending pathway long after completion of surgery. Clinicians should be alert to various causes and subclinical manifestations of mediastinitis.

#### ACKNOWLEDGMENTS

We thank Dr. Anna Derman for her assistance with radiographic imaging and interpretation and Dr. Anna Raphael for her editorial assistance. We thank the patient for his strength, courage and ability to overcome two rare, life-threatening diseases within a relatively short period of time.

#### CONFLICT OF INTEREST

None.

#### REFERENCES

- Athanassiadi KA. Infections of the mediastinum. *Thorac Surg Clin*. 2009;19(1):37-45.
- Farinas MC, Galo Peralta F, Bernal JM, et al. Suppurative mediastinitis after open-heart surgery: A case-control study covering a seven-year period in Santander, Spain. *Clin Infect Dis*. 1995;20(2):272-279.
- Trouillet JL, Vuagnat A, Combes A, et al. Acute poststernotomy mediastinitis managed with debridement and closed-drainage aspiration: factors associated with death in the intensive care unit. *J Thorac Cardiovasc Surg*. 2005;129(3):518-524.
- Life-threatening infections of the head, neck, and upper respiratory tract. In: Hall JB, Schmidt GA, Wood LD, eds. *Principles of Critical Care*, New York, New York: McGraw-Hill Medical;1998:887.
- Shaffer HA Jr, Valenzuela G, Mittal RK. Esophageal perforation. A reassessment of the criteria for choosing medical or surgical therapy. *Arch Intern Med*. 1992;152(4):757-761.
- Kono T, Kohno A, Kuwashima S, et al. CT findings of descending necrotizing mediastinitis via the carotid space ('Lincoln Highway'). *Pediatr Radiol*. 2001;31(2):84-86.
- Loyd JE, Tillman BF, Atkinson JB, Des Prez RM. Mediastinal fibrosis complicating histoplasmosis. *Medicine (Baltimore)*. 1988;67(5):295-310.
- Milano CA, Kesler K, Archibald N, et al. Mediastinitis after coronary artery bypass graft surgery. Risk factors and long-term survival. *Circulation*. 1995;92(8):2245-2251.
- Baldwin RT, Radovancevic B, Sweeney MS, et al. Bacterial mediastinitis after heart transplantation. *J Heart Lung Transplant*. 1992;11(3 Pt 1):545-549.
- Li KK, Varvares MA, Meara JG. Descending necrotizing mediastinitis: a complication of dental implant surgery. *Head Neck*. 1996;18(2):192-196.
- Mihos P, Potaris K, Gakidis I, et al. Management of descending necrotizing mediastinitis. *J Oral Maxillofac Surg*. 2004;62(8):966-972.
- Cirino LM, Elias FM, Almeida JL. Descending mediastinitis: a review. *Sao Paulo Med J*. 2006;124(5):285-290.
- Estrera AS, Landay MJ, Grisham JM, et al. Descending necrotizing mediastinitis. *Surg Gynecol Obstet*. 1983;157(6):545-552.
- Wheatley MJ, Stirling MC, Kirsh MM, et al. Descending necrotizing mediastinitis: transcervical drainage is not enough. *Ann Thorac Surg*. 1990;49(5):780-784.
- San Juan R, Chaves F, López Gude MJ, et al. Staphylococcus aureus poststernotomy mediastinitis: description of two distinct acquisition pathways with different potential preventive approaches. *J Thorac Cardiovasc Surg*. 2007;134(3):670-676.
- Konvalinka A, Errett L, Fong IW. Impact of treating Staphylococcus aureus nasal carriers on wound infections in cardiac surgery. *J Hosp Infect*. 2006;64(2):162-168.
- Diez C, Koch D, Kuss O, et al. Risk factors for mediastinitis after cardiac surgery - a retrospective analysis of 1700 patients. *J Cardiothorac Surg*. 2007;2:23.