

**Case Report**

# Fatal *Mycoplasma Pneumoniae* Infection: Case Report and Review of the Literature

Max Xiangtian Kong, MD;<sup>1</sup> Kia Newman, MD;<sup>1</sup> Ronald Goldenberg, MD;<sup>2</sup> Philip M. Tierno, Jr, PhD;<sup>1</sup> Irina Mikolaenko, MD;<sup>1</sup> Amy Rapkiewicz, MD<sup>1\*</sup>

<sup>1</sup> Department of Pathology, New York University Langone Medical Center, New York, NY

<sup>2</sup> Department of Medicine, New York University Langone Medical Center, New York, NY

***Mycoplasma pneumoniae* (*M. pneumoniae*) infection is rarely fatal in young adults. Most patients have no symptoms or mild nonspecific symptoms or signs with infection. Up to 3-10% infected people may develop pneumonia. We herein report a fatal case of *M. pneumoniae* infection presenting with acute respiratory failure and brain death in a 27 year old female. Autopsy revealed that diffuse alveolar damage in the lungs and acute hemorrhagic leukoencephalopathy (AHLE), a hyperacute form of acute disseminated encephalomyelitis (ADEM) in the brain.**

[*N A J Med Sci.* 2012;5(2):126-130.]

**Key Words:** *Mycoplasma pneumoniae*, diffuse alveolar damage, acute hemorrhagic leukoencephalopathy

## INTRODUCTION

Atypical pneumonia due to either *mycoplasma pneumoniae* (*M. pneumoniae*), *Chlamydia pneumoniae* or *Legionella pneumophila* has been thought to account for 7-20 % of community-acquired pneumonia. The incidence may be higher in patients with milder disease that can be managed in outpatients.<sup>1</sup> *M. pneumoniae* is one of the most common causes of atypical pneumonia in collected series from the United States and other parts of the world, and accounts for up to 35% of cases of pneumonia in outpatients and is responsible for up to 18% of cases in patients who need to be hospitalized.<sup>2</sup> Fatal infections however are rarely reported in associated with *M. pneumoniae*.<sup>3,4</sup> Herein, we report a rare case fatality resulting from diffuse alveolar damage (DAD), disseminated intravascular coagulation (DIC) and acute hemorrhagic leukoencephalopathy (AHLE) following a recent *M. pneumoniae* infection.

## CLINICAL HISTORY

A 27 year old female with no significant past medical history was admitted to NYU Tisch hospital for dyspnea. The patient gave a vague history of 6 months of feeling unwell, excessive fatigue with 15 lbs weight loss over the past 6 months. Over the past three weeks, she had some dry cough and noted painful cervical lymphadenopathy and malaise. She had intermittent high grade fever to 39.4 °C over the past three weeks. A chest x-ray (CXR) was performed in the 2 days prior to admission that was verbally reported as negative. She took one dose of clarithromycin.

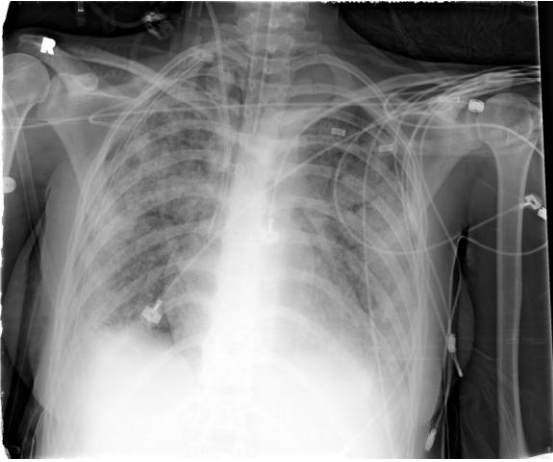
Prior to admission, she underwent a brain MRI as outpatient for evaluation of headaches which was non-revealing. On admission, her blood pressure was 105/62 mmHg, temperature 38.5 °C, pulse 72 bpm, respiratory rate 22/minute. The patient was hypoxemic with a PaO<sub>2</sub> of 64 mmHg. Non-rebreather mask oxygen was started. Intravenous fluids, vancomycin, ceftriaxone, azithromycin and oseltamivir were given. Physical examination showed the patient to be in respiratory distress and nebulizers were given. Decreased breath sounds and rales were noted at the lung bases. Her laboratory findings are shown in **Table 1**. Significant findings in her hospital course are as follows:

On the 7<sup>th</sup> hospital day, her oxygen saturation dropped to 77% on facemask increasingly requiring continuous positive airway pressure (CPAP) for extended periods of time. Arterial blood gas (ABG) showed pCO<sub>2</sub> 51(normal 35-45) mmHg, pH 7.26 (normal 7.35-7.45). She was intubated. She developed acute kidney insufficiency (AKI) with elevated creatinine to 2.4 mg/dL from baseline of 0.5 mg/dL. An open lung biopsy was performed that showed DAD in an acute and organizing pattern in all specimens taken from the right mid and right lower lobes. Stains for microorganisms, including viral stains (HSV1 and 2, adenovirus, and CMV, acid fast bacilli for mycobacterium tuberculosis as well as a GMS stain for fungus and *Pneumocystis jirovecii* (PCP), are negative. CXR was followed daily showing progressing moderately to severe diffuse bilateral air space disease (**Figure 1**). Steroids were also started. The patient's AKI worsened and she became hyperkalemic (K=6.4 mEq/L) requiring continuous veno-venous hemofiltration (CVVH). She developed acute liver insufficiency with AST elevated to 11,000 U/L. Her PT, PTT and INR were elevated and were

Received 2/9/2012; Revised 3/15/2012; Accepted 3/30/2012

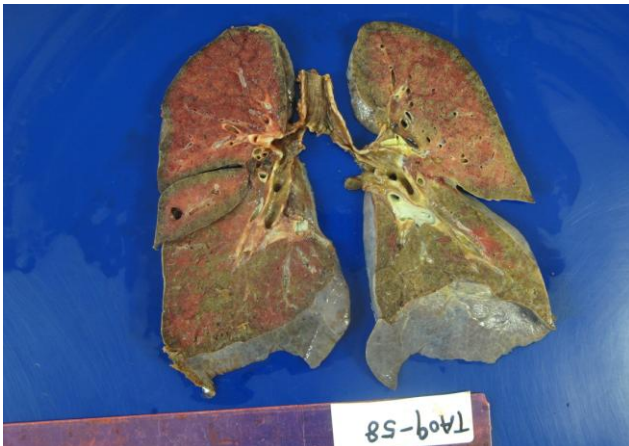\*Corresponding Author: NYUMC/Bellevue Hospital, 462 First Avenue 4W39, New York, NY 10016. Tel: 212-562-3421.

(Email: Dramyrap@gmail.com)



**Figure 1.** Chest X-ray, one day before the patient died, showed severe diffuse bilateral air space disease.

unresponsive to FFP and Vitamin K. D-dimer elevation was seen and a diagnosis of DIC was made. To rule out embolic causes of thrombosis, a transthoracic echocardiogram (TTE) showed right atrium and right ventricle dilatation on the 9<sup>th</sup> hospital day. Upper GI endoscopy on the 11<sup>th</sup> hospital day showed diffuse hemorrhagic mucosa with oozing from the entire mucosal surface of the stomach. Hematin was found in the gastric fundus. Lower extremities Dopplers obtained showing positive DVT for both sides and an Inferior Vena Cava filter was placed on the same day. The patient was noted to have partial left sided seizures on the 12<sup>th</sup> hospital day. The patient exhibited worsening neurologic status with pupils fixed and dilated non reactive to light, absent GAG reflex, no higher cortical function, no spontaneous movement and was unresponsive to noxious stimuli. Non-contrast head Cat Scan was performed on the 14<sup>th</sup> hospital day, with the results showing midline shift with mass effect and diffuse subtle loss of gray white differentiation indicating diffuse anoxia. The patient was taken off the ventilator on the 17<sup>th</sup> hospital day and was pronounced dead at 4:35 pm the same day. A full unrestricted autopsy was performed upon the parent's request.

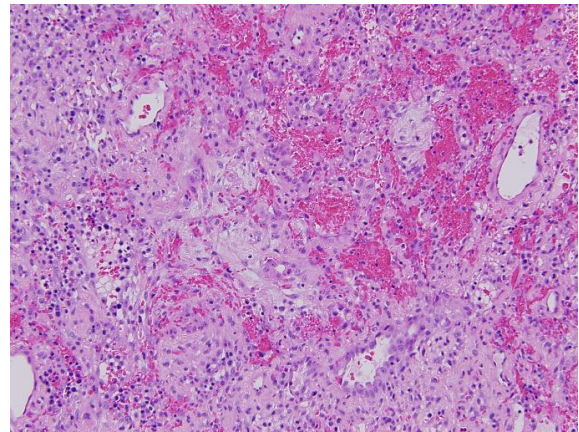


**Figure 2.** Diffuse consolidation and hemorrhage in both right and left lungs, most severe in the bilateral upper lobes and right middle lobe (10% formalin fixed overnight).

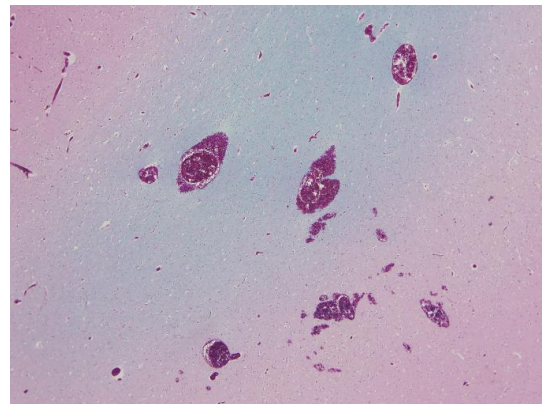
## AUTOPSY FINDINGS

The left pleural cavity contains 200ml of bloody fluid (postmortem change). The right pleural cavity contains 10ml of bloody fluid with the thoracostomy in place. The lungs weigh 1870 gm combined (right lung 1000 gm (N=360-570); left lung 870 gm (N=325-480). Sectioning demonstrates diffuse consolidation and hemorrhage in both right and left lungs, most severe in the bilateral upper lobes and right middle lobe (**Figure 2**).

Microscopically, peribronchiolar inflammation was seen and focal bronchial squamous metaplasia. The alveolar spaces are filled with proteinaceous exudates, cellular debris, fibrin deposition and hyaline membranes. Proliferation of type 2 pneumocytes with reactive changes and cellular expansion of alveolar septae with loose connective tissue are seen (figure 3). The lung tissue is extensively involved. There is mild interstitial chronic inflammation with lymphocytes, plasma cells and histiocytes as well as occasional neutrophils (**Figure 3**). No viral inclusions, granulomas, foci of necrosis or acute pneumonia are seen. The features are consistent with DAD, acute and organizing pattern. PCR studies were performed on lung tissue but failed to reveal *M. pneumoniae*.



**Figure 3.** Representative section of the lungs showed proliferation of type 2 pneumocytes with reactive changes and cellular expansion of alveolar septae by connective tissue, chronic lymphoplasmacytic infiltrates as well as edema. Note prominent hemorrhage. (Hematoxylin-Eosin, original magnification x 100).



**Figure 4.** Representative section of the brain showed scattered ring and ball-shaped hemorrhages predominantly involving the white matter (Luxol fast blue stain original magnification x 20).

The brain weighed 1330 grams. There was evidence of diffuse cortical edema with associated central diencephalic and bilateral uncus and parahippocampal herniations. Coronal sectioning of the cerebral hemispheres revealed multiple punctuate hemorrhages, predominantly localized in the white matter of the cerebrum and cerebellum. Microscopic sections of the cerebral and cerebellar white matter showed changes consistent with AHLE with numerous small and occasional larger foci of ring and ball-shaped perivascular hemorrhages

(Figure 4). Focally, the gray matter was also involved. There were scattered foci of loss of myelin staining (demyelination) centered around small veins or venules. Majority of the fibers in the areas of loss of myelin staining were demyelinated, but some showed axonal fragmentation. Many blood vessels in the areas of demyelination and hemorrhage were surrounded by a marked inflammatory infiltrate with predominance of neutrophils.

**Table 1.** Pertinent laboratory results.

Test	Value (Hospital Day #)	Value (Hospital day #)	normal range
M. pneumonia antibodies IgM *	<b>0.86-1.01</b> U/L (1)	<b>0.80-0.88</b> U/L (4)	<= 0.76 U/L
IgG*	<b>0.62-1.23</b> U/L (1)	<b>0.71-0.93</b> U/L (4)	<= 0.09 U/L
serum anti-RSV IgM	0.74 IV (4)		<= 0.89 IV
serum anti-RSV IgG	<b>1.50</b> IV (4)		<= 0.89 IV
Hemoglobin/hematocrit	11.8/34.5 (1)	<b>7.0/21.6</b> (12)	12.5-15g/dL/36-44%
WBC	6.2 (1)	<b>26.2</b> (15)	4.5-10x 10 <sup>3</sup> cells/ml
Platelet	123 (1)	<b>80</b> (11)	100-450x10 <sup>3</sup>
Bilirubin, total	0.1 (1)	<b>4.6</b> (16)	0.1-1.2 mg/dL
Bilirubin, direct	0 (1)	<b>2.3</b> (16)	0-0.3 mg/dL
H1N1 RNA Qnt Real- time PCR	negative (1)		
Scl-70 antibody	negative (1)		
Rheumatoid factor	negative (1)		
MPO	negative (1)		
PR3	negative (1)		
Heparin PF4	negative (1)		
Ds-DNA	negative (1)		
ANCA	negative (1)		
ANA	negative (1)		
HIV	negative (1)		
Nasal swab influenza A+B	negative (1)		
Infectious mononucleosis	negative (1)		
Chlamydia pneumonia IgM	<1:20 (1)		< 1:20
Chlamydial pneumonia IgG	<:1:64 (1)		< 1:64
Legionella antigen	negative (1)		
Legionella antigen/antibody	negative (1)		
Measles, rubeola IgM Ab	0.32 AU (1)		< 0.79 AU
Cryoglobulin level	negative (1)		
C3	<b>71</b> (1)		100-233 mg/dL
D-Dimer, plasma	<b>1785</b> (1)		< 200 ng/mL
Sputum culture	negative (1)		
Sputum viral panel	negative (1)		
Blood culture	negative (1)		
Urine culture	negative (1)		
Vaginal culture	positive for Lactobacillus(1)		
Vaginal PCR for gonorrhea/Chlamydia	negative (1)		
Fibrinogen	<b>478</b> (10)		224-412 mg/dL
AST	<b>49</b> (1)	<b>11,000</b> (10)	8-20 U/L
ALT	28 (1)	<b>3300</b> (10)	8-20 U/L
Urea nitrogen, blood	7 (1)	<b>33</b> (10)	8-20 mg/dL
Creatinine, serum	0.9 (1)	<b>4.5</b> (10)	0.7-1.5 mg/dL

\*Blood was drawn twice on hospital day 1 and 4, repeated tests were done.

## DISCUSSION

*M. pneumoniae* infection is one of the most common causes of atypical community acquired pneumonia. Pneumonia due to *M. pneumoniae* is usually mild and not infrequently the infection itself is asymptomatic. *M. pneumoniae* accounts for up to 35% of cases of pneumonia in outpatients and is responsible for 3-18% of cases in patients who require hospitalization. It is uncommon for *M. pneumoniae* to present in a fulminant and fatal manner. The fatal complications of *M. pneumoniae* infection are not well established but include acute respiratory distress syndrome, acute disseminated encephalomyelitis (ADEM), DIC, hemophagocytic syndrome and Steven's Johnsons syndrome. Rare cases of fatal myocarditis have been reported.

The most comprehensive review of fatal *M. pneumoniae* infection was performed by Chan and Welsh.<sup>5</sup> They reviewed 46 cases of *M. pneumoniae* infections in the period of 1966 to 1991. They divided *M. pneumoniae* infection into three categories based on the patients' outcome as nonfatal respiratory failure (n = 26), fatal respiratory failure (n = 13), and fatal nonrespiratory failure (n = 7). Only two cases presented as both fatal respiratory failure and brain death in their review. They emphasized that fulminant cases seem to be more common in young healthy adults, in males, and possibly in smokers. Archer and Wall<sup>6</sup> recently reported two cases that presented with CNS symptoms and developed brain death quickly. Both patients died of AHLE.

The autopsy in this patient confirmed the premortem diagnosis of DAD and established the diagnosis of ALHE. Clinically, the diagnosis of DIC was made based on her serology and evidence of thrombosis. This is supported by the findings of petechial hemorrhage and splenic infarction on autopsy. DIC probably contributed to the development of AKI and acute liver failure in this patient. The anemia and cyanosis of her fingertips raises the question of autoimmune hemolytic anemia with cold agglutinin formation, which was not tested premortem. An elevated *M. pneumoniae* titer (IgM and IgG) confirmed a recent infection. No other source of infection was identified with extensive laboratory tests (table 1). As DAD is an end-stage process, frequently the underlying or precipitating cause of the disease is not apparent. DAD due to *M. pneumoniae* does not show any specific morphologic features to suggest the bacteria as a cause. In areas of the lung which are less affected one may see non-specific changes associated with atypical pneumonia such as peribronchiolar chronic inflammation and bronchitis. PCR can be used to confirm the presence of the bacteria. The sensitivity is reported as 92% with respiratory secretions or tissue,<sup>7</sup> and the real time PCR has a lower limit of detection of 1000 organisms/ml. The specificity is close to 100%. However, failure to identify any pathogen is found in nearly 50% of cases even using the serologic and molecular techniques.<sup>8</sup> The post mortem interval could be an important factor that can affect the sensitivity.

The mechanisms by which *M. pneumoniae* produces

infection for humans are believed to be immune-mediated rather than induced directly by the bacteria. The theory is supported by the observations that children infrequently develop serious lung infections despite evidence of infection. In addition, the antibodies produced against the glycolipid antigens of *M. pneumoniae* may act as autoantibodies due to the cross reaction with human red cells and brain cells. Cell mediated immunity may also play a role in the development of acute respiratory failure, especially the function of macrophage-derived cytokines interleukin 8 (IL-8) and IL-18.<sup>9</sup> Some clinical studies suggest that steroids may be of some value in dampening the immune response in patients that have fulminant *M. pneumoniae* infections to prevent further complications.<sup>10,11</sup> This patient despite receiving steroids and antibiotics succumbed to the disease.

The main neuropathological findings were consistent with the diagnosis of AHLE, or more commonly referred to as Hurst's Disease. AHLE is a rare, rapidly progressive and usually fatal demyelinating condition affecting the central nervous system. AHLE was first described in 1941 by Weston Hurst<sup>12</sup> and later by Adams in 1949.<sup>13</sup> Since these first descriptions, there have been less than 100 adults, and 10 pediatric cases of AHLE reported in the literature. The disease can occur in all age groups but is rare in the elderly. It is widely hypothesized that because AHLE shares many clinical features with ADEM, the two are part of a spectrum of diseases rather than two distinct entities. Most patients with ADEM will recover while AHLE progresses rapidly, from confusion to stupor to coma; death usually results an average of six days after the onset of symptoms. In 50% of patients there is a prodromal febrile illness and almost always an upper respiratory infection. The CT and MRI findings may have edema, punctuate hemorrhages and mass effect. Laboratory findings are nonspecific. At autopsy the brain shows multiple petechial hemorrhages involving the grey and white matter. Large hemorrhages, asymmetric necrosis and cavitation may also be present. Affected gray matter is discolored and edematous. Microscopically, perivascular demyelinating lesions with ball or ring hemorrhages surrounding necrotic venules are observed (figure 4). There may be mononuclear cells and neutrophils depending on the length of the illness. It is suspected that the infection that precedes AHLE may induce a hyperacute autoimmune process through immunological cross-recognition of central nervous system antigens. Treatment is usually with steroids but despite aggressive treatment AHLE is usually rapidly fatal.

Fatal complications of common usually banal infections can occur despite appropriate therapy. The autopsy remains an extremely useful tool to further delineate the unexpected course of common disease processes. This case demonstrates fatal respiratory and neurologic complication of *M. pneumoniae* infection in a young adult. The fatal complications of *M. pneumoniae* infection may underscore immune dysregulation which is caused by this infection.

**CONFLICT OF INTEREST**

The authors have no conflict of interest to disclose.

**REFERENCES**

1. Hammerschlag MR. Mycoplasma pneumonia infections. *Curr Opin Infect Dis.* 2001;14(2):181-186.
2. Luby JP. Pneumonia caused by mycoplasma pneumoniae infection. *Clin Chest Med.* 1991;12(2):237-244.
3. Fishman RA, Marschall KE, Kislak JW, et al. Adult respiratory distress syndrome caused by mycoplasma pneumoniae. *Chest.* 1978;74(4):471-473.
4. Scully RE, Mark EJ, McNeely WF, et al. Case records of the Massachusetts General Hospital. Weekly clinicopathological exercises. Case 5-1992. A 20-year-old man with diffuse pulmonary infiltrates and disseminated intravascular coagulation. *N Engl J Med.* 1992;326(5):324-336.
5. Chan ED, Welsh CH. Fulminant Mycoplasma pneumoniae pneumonia. *West J Med.* 1995;162(2):133-142.
6. Archer H and Wall R. Acute haemorrhagic leukoencephalopathy: two case reports and review of the literature. *J Infect.* 2003;46(2):133-137.
7. Blackmore TK, Reznikov M, Gordon DL. Clinical utility of the polymerase chain reaction to diagnose Mycoplasma pneumoniae infection. *Pathology.* 1995;27(2):177-181.
8. Templeton KE, Scheltinga SA, van den Eeden WC, et al. Improved diagnosis of the etiology of community-acquired pneumonia with real-time polymerase chain reaction. *Clin Infect Dis.* 2005;41(3):345-351.
9. Narita M. Pathogenesis of neurologic manifestations of mycoplasma pneumoniae infection. *Pediatr Neurol.* 2009;41(3):159-166.
10. Miyashita N, Obase Y, Ouchi K, et al. Clinical features of severe Mycoplasma pneumoniae pneumonia in adults admitted to an intensive care unit. *J Med Microbiol.* 2007;56(Pt 12):1625-1629.
11. Radisic M, Torn A, Gutierrez P, et al. Severe acute lung injury caused by mycoplasma pneumoniae: Potential role for steroid pulses in treatment. *Clin Infect Dis.* 2000;31(6):1507-1511.
12. Hurst EW. Acute hemorrhagic leukoencephalitis: a previously undefined entity. *Med J Aust.* 1941;2(1):1-6.
13. Adams RD, Cammermeyer J, Denny-Brown D. Acute necrotizing hemorrhagic encephalopathy. *J Neuropath Exp Neurol.* 1949;8(1):1-29.