

Case Report

Nail Lacquer: A Common Artifact That May Go Unrecognized

Alexandra E. Reis, BA;* Ajay N. Amarnani, MD;
Christopher A. D'Angelis, MD, PhD; Thomas N. Helm, MD

Department of Dermatology, Jacobs School of Medicine and Biomedical Sciences, University at Buffalo, Buffalo, NY

Nail specimens are being submitted with increased frequency to confirm a diagnosis of onychomycosis, diagnose an inflammatory dermatosis, or identify clues to an underlying neoplasm. Samples often are associated with a variety of lacquers (aka polish, varnish, enamel) or gels that may vary in their appearance. Some lacquers or gel polishes add challenges to maintaining an even plane of sectioning, obscure underlying findings, or separate from the nail in processing and be misinterpreted as terra firma. We review the histologic appearance of common lacquers and gel polishes so that dermatopathologists recognize these different presentations in clinical practice.

[*N A J Med Sci.* 2017;10(2):65-69. DOI: 10.7156/najms.2017.1002065]

Key Words: *nail polish, nail cosmetics, lacquer, histologic artifact, nail plate, nail unit, onychomycosis*

INTRODUCTION

Attractive nails are essential to a well groomed appearance, and healthy nails are highly desirable.¹ Nail cosmetics are commonly used to enhance the appearance of the nails, and can also be used to conceal nail abnormalities related to aging, onychomycosis and psoriasis.² In the United States, nail polish sales have reached multimillion dollar levels and continue to increase, while the total dollar amount spent on salon nail services exceeded eight billion in 2014.³⁻⁵ Today, a wide variety of nail cosmetics are readily available and commonly used including nail lacquer and UV fixed gel polish.²

The traditional nail lacquer or polish formulation that is used today first became available in the early twentieth century.⁶ Nail lacquer is comprised of nitrocellulose dissolved in organic solvents. Solvents are modified with plasticizers or resins to soften the nitrocellulose film, and pigments are suspended within the mixture to add color.⁶ Nail polish may be translucent, pigmented or transparent and may be associated with a number of finishes including glitter, shimmer, gloss or matte. Nail salons generally apply a few layers of polish and allow the polish to dry before applying another layer. A base coat to protect the nails and enhance adhesion may be applied beneath the polish, while a top coat can be used to increase the durability of the polish.²

Gel polish, shellacs, or UV curable nail lacquers are a newer type of nail cosmetic, and have become increasingly popular in recent years. Gel polish is now one of the most requested

services at nail salons, and gel polish systems have also recently been made available for home use.⁷⁻⁸ As opposed to traditional nail lacquer, gel is fixed to the nail with UV light and may adhere to the nail without chipping for two to three weeks.⁸⁻¹⁰ The gel is generally applied in three layers – a basecoat, one or two layers of pigmented gel polish, and a top coat. These layers are applied with a brush, directly to the nail plate.¹¹ The application of each coat is followed by exposure to UVA light to harden and cure the gel polymers.¹² While traditional polish or lacquer may be removed completely with acetone, gel polish often requires buffing with a file or another tool, which could result in nail damage. Gel polish itself may also cause damage to and thinning of the nail plate.¹⁰

Nail clippings are routinely submitted to confirm the diagnosis of onychomycosis, inflammatory disease states, or pigmented lesions.¹³ Histopathology is often required to differentiate these conditions as they can appear clinically similar.¹⁴ As nail lacquer and gel polish are widely used, clippings taken for diagnostic purposes are frequently associated with nail cosmetics. Though common, the histology of nail cosmetics has not yet been fully characterized. A previous article identified three distinct patterns associated with nail polish, however the study was retrospective and the types of polish were not known.¹⁵ Another recent study described the microscopic characteristics of six types of nail cosmetics, but was limited by one sample of each type.¹⁶ A third recent study correlated the color of the nail polish to the histologic findings, but not to the finish of the polish.¹⁷ Understanding and recognizing the histology of common nail cosmetics including lacquer and gel polish, as well as their gross clinical appearance will aid dermatopathologists in accurate clinical diagnoses.¹⁸

Received: 01/31/2017; Revised: 02/28/2017; Accepted: 04/15/2017

*Corresponding Author: 32 St. Catherine's Court Buffalo, NY 14222. Tel: 716-812-4871. (Email: aereis@buffalo.edu)

METHODS

Nail polish (lacquer) brands were chosen based on their worldwide popularity and availability. Five best selling colors were selected and gel polishes were chosen based on visual similarity to the lacquer colors. Five additional nail polishes were then selected to encompass a broad range of popular lacquer finishes.

Nail cosmetics were applied to a volunteer's nails via a classic or gel manicure at a local nail salon. First, the nails were cleaned and soaked in warm water. The cuticles were trimmed, and the nails were filed. Nail polish was applied in three layers – a basecoat, colored nail polish, and a top coat. The nails were

allowed to air dry between each coat for the traditional nail polish manicure. The nails were placed under UV light for two minutes between each of the three coats during the gel polish application. The polish remained on the nails for twenty-four hours before clippings were taken. Thirteen out of the fifteen samples were processed and stained with hematoxylin and eosin. Two samples were unable to be successfully processed. Images of the samples stained with hematoxylin and eosin were captured, and images were also collected under a polarizing light source with either 20 or 40x magnification. To characterize our findings, we used three categories established by a previous study, and describe two more.

Table 1. Nail Cosmetic Histological Patterns.

Pattern	Characteristics
1	Linear hyperpigmentation with diffuse fine granular material, non polarizable
2	Linear layered material with polarizable band
3	Linear hyperpigmentation with larger granules and crystals of polarizable material
4	Linear hyperpigmentation with diffuse fine granular material, polarizable

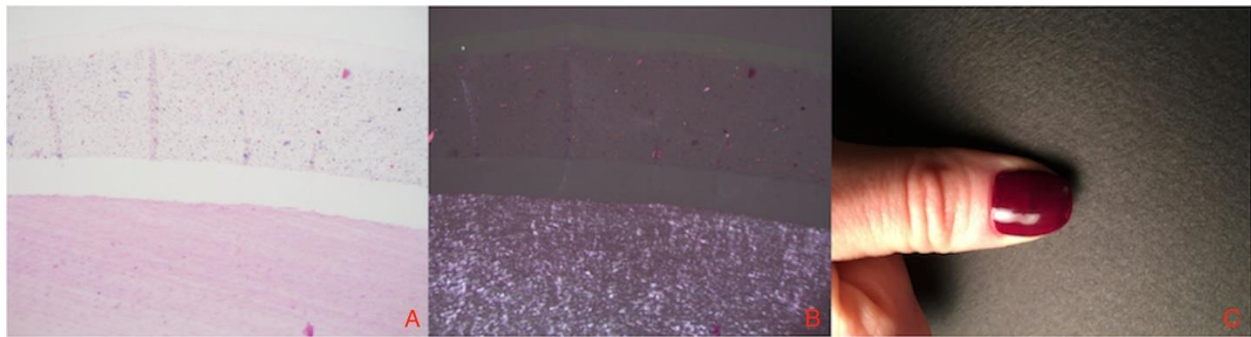


Figure 1. Pattern 1. Linear hyperpigmentation with diffuse granular material. Distinct 3 layered gel pattern.
 A) Hematoxylin and eosin stained section at 20x magnification.
 B) Under polarized light source at 20x magnification, scant polarizable material, non polarizable overall.
 C) Gross clinical appearance of the nail, solid gel polish with gloss finish.

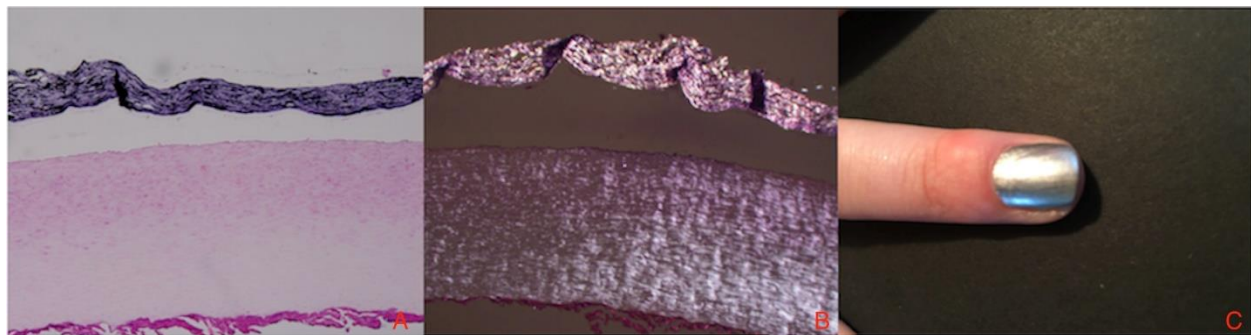


Figure 2. Pattern 2. Linear layered hyperpigmentation that mostly polarizes in a band.
 A) Hematoxylin and eosin stained section at 40x magnification.
 B) Under polarized light source at 40x magnification.
 C) Gross clinical appearance of the nail: metallic lacquer.

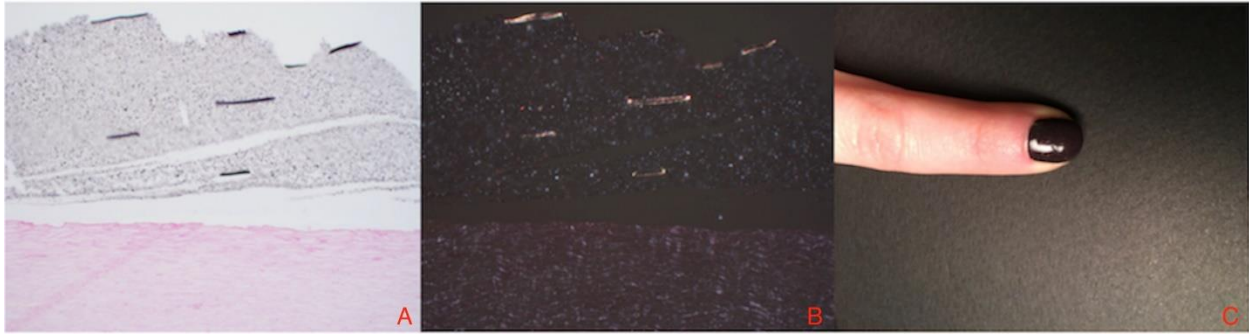


Figure 3. Pattern 3. Hyperpigmentation with linear granules.
 A) Hematoxylin and eosin stained section at 40x magnification.
 B) Under polarizing light source at 40x magnification.
 C) Gross clinical appearance of the nail: micro glitter lacquer.

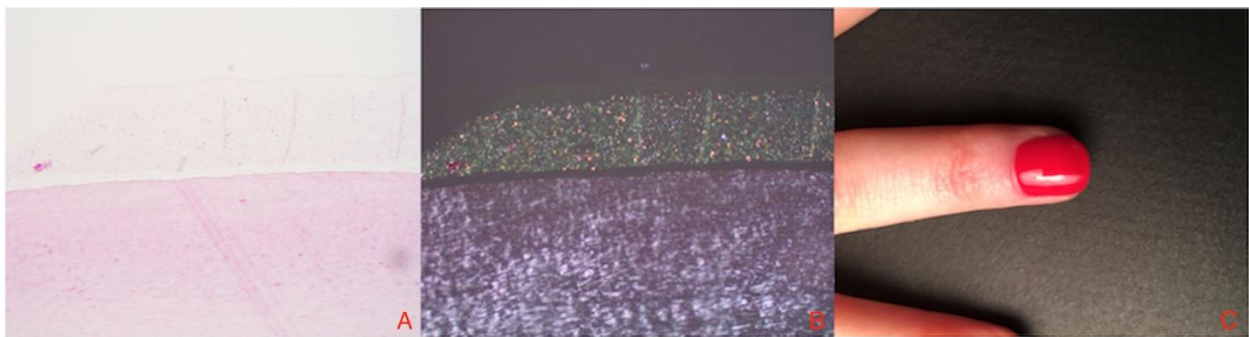


Figure 4. Pattern 4. Non linear hyperpigmentation with diffuse fine granules. Distinct three layered gel pattern.
 A) Hematoxylin and eosin stained section at 20x magnification.
 B) Under polarizing light source at 20x magnification.
 C) Gross clinical appearance of the nail: solid gel polish with gloss finish.

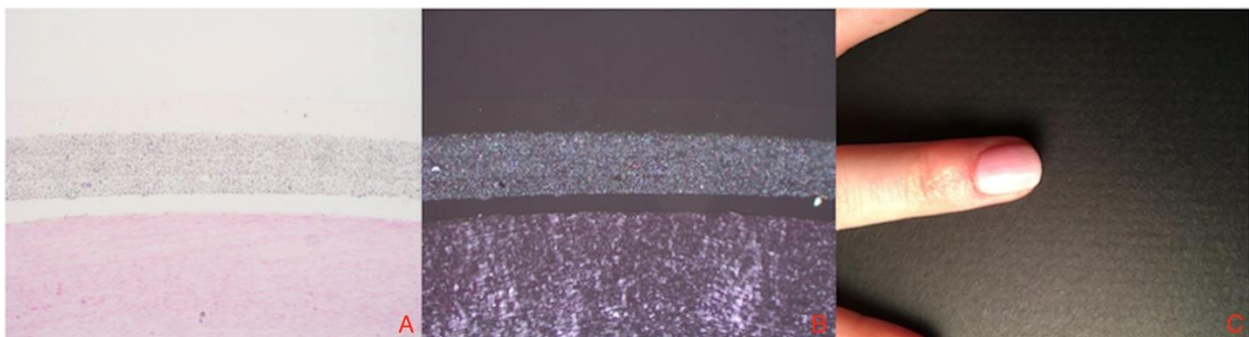


Figure 5. Gel Pattern. Linear hyperpigmentation with diffuse fine granular material, polarizable. Distinct three layered gel pattern.
 A) Hematoxylin and eosin stained section at 20x magnification.
 B) Under polarizing light source, 20x magnification.
 C) Gross clinical appearance of nail: solid gel polish with gloss finish.

RESULTS

We observed four patterns with distinct histological characteristics that can be correlated with the clinical appearance of the lacquer or gel nail polish (**Table 1**). We also noted distinct features that are exclusive to gel polish, for a total of five patterns. The first three patterns have been previously described.¹⁵ The first pattern described in an earlier

study is linear hyperpigmentation with diffuse granular material and no apparent polarizable base.¹⁵ Three of our thirteen processed samples fit this category. (Figure 1) Grossly, this pattern is representative of solid colored nail polish with a gloss finish. The second previously described pattern is linear, layered material that polarizes in a band.¹⁵

Two of our thirteen processed samples fit this description closely (**Figure 2**). Grossly, this pattern represents metallic nail lacquer without glitter. The third previously described morphology is linear hyperpigmentation with larger granules and crystals of polarizable material.¹⁵ Four of our thirteen samples fit this pattern, and grossly this pattern corresponds to nail cosmetic with a glitter finish (**Figure 3**). The fourth pattern observed was non linear hyperpigmentation with fine diffuse polarizable material. Four of our thirteen samples fit this pattern (**Figure 4**). Grossly, this pattern appears as a solid colored nail polish with gloss finish. Finally, gel nail polish is demonstrably thicker in appearance than traditional lacquer nail polish and can be characterized by three distinct layers (**Figure 1, Figure 4, Figure 5**).

DISCUSSION

Though traditional nail lacquer is composed of a nitrocellulose base with suspended pigments while gel polish is made from methacrylate and acrylate polymers, the pigment used in each type of nail cosmetic is similar.² Three out of our four patterns are based on histologic patterns related to the pigment irrespective of the type of nail cosmetic. Pattern 2 was associated only with metallic lacquer, but a metallic gel polish was not sampled. The other three patterns were associated with both gel and lacquer polish.

We found further evidence of the first three patterns previously described by an earlier study, and describe a new fourth pattern.¹⁵ Our fourth pattern differs from the first described pattern only in the amount of polarizable material, however these differences are not grossly evident. The amount, color and birefringence varied from sample to sample, but all of the samples from categories 1 and 4 grossly present as solid colored polish with a glossy finish. An earlier study conjectured that polarizable crystals present in the samples correlated to sparkling particles grossly evident in the polish.¹⁵ While we did find this to be the case for large linear polarizable particles in the third pattern that appeared grossly as glitter polish, the smaller fine diffuse polarizable particles characteristic of our fourth pattern appeared grossly as solid nail polish.

Interestingly, a previously described category was characterized by polish with linear layered material that polarizes in a band.¹⁵ This was not observed in our study. However, we did observe two samples that polarized nearly completely, and these samples correlated grossly to metallic polish. Our sample also contained 3 bands, but they were not as pigmented as pictured in the previous study.¹⁵ Based on our findings, it is possible that their sample may have also been comprised of metallic polish or potentially metallic gel polish.

The histologic features of gel polish may be used to differentiate between gel polish and traditional lacquer. Three distinct layers can be seen in each of our gel samples. These layers correspond to a base coat that adheres to the nail, a layer of colored gel polish, and a top coat. Another recent study also noted the findings of three distinct layers present in gel polish samples.¹⁶ In our gel samples, the base and top coat appear

translucent and devoid of pigment. The base coat creates a larger well defined linear space between the nail plate and the pigmented polish in the gel samples than in the traditional polish samples, and this feature can be used to distinguish gel polish from other types of nail cosmetics. Though each of our nail lacquer samples were applied in three layers with a base coat, the base coat can not be seen in the majority of the lacquer samples. Spaces that exist between the nail lacquer and the surface of the nail appear irregular and less uniform than in the gel polish samples. It is possible that the base coat in the lacquer samples was washed away or destroyed as a result of processing while the gel base coat persisted.

Another distinguishing feature of gel nail polish is that it is considerably thicker than traditional nail lacquer. While the entire thickness of the nail polish can be seen under 40x magnification for the traditional nail polish samples, it was necessary to use 20x magnification to capture the entire thickness of the gel sample. Defect where the polish became separated from the nail plate or folded back occurred exclusively in the lacquer polish samples, and this may be another feature used to distinguish traditional nail lacquer from gel.

Nail lacquer and gel nail polish have the potential to be misinterpreted histopathologically as pigmented nail lesions. These common nail cosmetics may also obscure important findings on nail clippings submitted for evaluation of pigmented lesions, onychomycosis, an artifact, or other nail plate disorders. Nail lacquer may also cause difficulty in processing and cutting of specimens. Polariscopic examination highlights the refractile particles and aids in diagnosis and differentiation. The underlying nail plate is not significantly altered by nail lacquer and therefore underlying dermatoses and nail dystrophies should still be identifiable. Understanding the histologic patterns associated with nail lacquer and gel polish may help to avoid misinterpretation and associated costly workups, and will aid dermatopathologists in accurate clinical diagnosis.

CONFLICT OF INTEREST

None.

REFERENCES

1. Reich A, Szepietowski JC. Health-related quality of life in patients with nail disorders. *Am J Clin Dermatol*. 2011;12:313-320.
2. Jefferson J, Rich P. Update on nail cosmetics. *Dermatol Ther*. 2012;25:481-490.
3. Global Premium Nail Polish Market 2015-2019 - Forecasts the Global Premium Nail Polish Market to Grow at a CAGR of 6.23% Over the Period 2014-2019. *Business Wire*. 2016. http://www.researchandmarkets.com/research/xqkdjt/global_premium. Accessed August 8th, 2016.
4. Brookman, F. Aiming for New Lengths: Nail Trends Heat Up in 2013. *WWD*. 2013. <http://wwd.com/business-news/retail/critical-mass-nail-care-gains-steam-6654908>. Accessed August 8th, 2016.
5. Nails 2015 Big Book Statistics. *Nails Magazine*. 2016. <http://files.nailsmag.com/Feature-Articles-in-PDF/NABB2015-16stats.pdf>. Accessed August 8th, 2016.
6. Schlossman ML, Wimmer EP. The history of nail polish. *Cosmet Toiletries*. 1992; 9:115.
7. Meisel M. Style at their fingertips: a look at 50 years of nail polish innovations. *Household & Personal Products Industry*. 2013;50:46-49.

8. Barnes J. Show of hands: innovations in gel polishes up the ante for spa manicures, preserving nails and improving your spa's loyal client base. *American Spa*. 2014;7:62-63.
9. Sun C, Koppel K, Adhikari K. Sensory factors affecting female consumers' acceptability of nail polish. *Int J Cosmetic Sci*. 2015;37:642-650.
10. Chen AF, Chimento SM, Hu S, Sanchez M, Zaiac M, Tosti A. Nail damage from gel polish manicure. *J Cosmet Dermatol*. 2012;11:27-29.
11. Dahlin J, Berne B, Dunér K, et al. Several cases of undesirable effects caused by methacrylate ultraviolet-curing nail polish for non-professional use. *Contact Dermatitis*. 2016;75:151-156.
12. Madnani N, Khan K. Nail cosmetics. *Indian J Dermatol VE*. 2012;78:309.
13. Wilsmann-Theis D, Sareika F, Bieber T, Schmid-Wendtner MH, Wenzel J. New reasons for histopathological nail-clipping examination in the diagnosis of onychomycosis: PAS-staining in the diagnosis of onychomycosis. *J Eur ACAD Dermatol*. 2011;25:235-237.
14. Stephen S, Tosti A, Rubin AI. Diagnostic applications of nail clippings. *Dermatol Clin*. 2015;33:289-301.
15. Anolik RB, Elenitsas R, Minakawa S, Nguyen J, Rubin AI. Histologic features of nail cosmetics. *Am J Dermatopath*. 2012;34:412-415.
16. Zimmer KA, Clay T, Vidal CI et al. Microscopy of Common Nail Cosmetics. *Am J Dermatopath*. 2017;1:1-5.
17. Fernandez-Flores A. Morphology of rare exogenous materials in dermatopathology. *J Cutan Pathol*. 2017;44:237-248.
18. Reis A, Amarnani A, D'Angelis C, Helm T. Nail lacquer: a common artifact that may go unrecognized. Poster presented at the American Society of Dermatopathology 53rd Annual Meeting; 2016, October 27 - 30; Chicago, IL.