

## Case Report

# Cavernous Hemangioma of the Uvula: Report a Rare Case with Literature Review

Minhua Wang, MD, PhD;<sup>1</sup> Samuel Chen;<sup>2</sup> Wilfrido D. Mojica, MD;<sup>1</sup>  
Frank Chen, MD, PhD, MBA<sup>1,3,\*</sup>

<sup>1</sup> Department of Pathology, Buffalo General Medical Center, State University of New York, Buffalo, NY; <sup>2</sup> City Honors School, Buffalo, NY  
<sup>3</sup> Clinical Lab, Medina Hospital, Quest Diagnostics, Medina, NY

**Hemangiomas of the oral cavity are relatively rare with a prevalence rate of less than 1%, mostly involving lips, tongue, buccal mucosa, and palate. Cavernous hemangioma is a subtype of hemangioma. The involvement of uvula by a cavernous hemangioma is extremely rare. To date, only 4 cases have been reported in the English literature. Here we report one such case with analysis of its histologic and immunohistochemical features. The patient is a 58-year-old white male with a mass on the left side of his uvula. Because a simple excision of this lesion would have rendered the inferior portion of the uvula pedunculated, possibly causing a globus sensation, a partial uvulectomy was done to maintain the integrity of the remaining uvular structure. Grossly, the lesion was a tan-pink polypoid mass partially covered by squamous mucosa, measuring 0.8 x 0.5 x 0.3 cm. Microscopic examination revealed poorly circumscribed large cavernous spaces lined by flattened endothelium, separated by scant connective tissue, morphologically consistent with cavernous hemangioma. Immunohistochemical study showed that CD34 stain highlighted the endothelial cells, supporting this diagnosis. By reporting this case with rare erratic location of cavernous hemangioma, we like to raise the awareness that cavernous hemangioma is also in the differential diagnosis when a patient presents with an elongated uvula or uvular mass.**

[*NA J Med Sci.* 2015;8(1):56-58. DOI: 10.7156/najms.2015.0801056]

**Key Words:** cavernous hemangioma, uvula, benign vascular tumor

## INTRODUCTION

Hemangiomas are benign vascular tumors composed of blood vessels of various sizes lined by plump to flattened endothelial cells without atypia. Hemangiomas involving oral cavity are relatively rare, with a prevalence of 8 in one thousand males and 4 in one thousand females.<sup>1</sup> Cavernous hemangioma affecting the uvula is an extremely rare event. To our knowledge, there have only been 4 cases reported in the English literature. Here we report one additional case of uvular hemangioma.

## CASE REPORT

The patient is a 58-year-old Caucasian male who presented with a uvular mass, which was incidentally found during his visit to a dermatology clinic. The mass was blue in color and extended along a portion of the uvula on the left side. Cautious assessments revealed that a simple excision of this lesion and/or biopsy in the office would have rendered the inferior portion of the uvula pedunculated, which may cause a globus sensation. The patient elected to receive a partial uvulectomy to maintain the integrity of the remaining uvular structure.

Grossly, the excised portion of the uvula was a tan-pink polypoid mass, measuring 0.8 x 0.5 x 0.3 cm. Microscopic examination revealed poorly circumscribed collections of large cyst-like dilated vessels lined by flattened endothelium, consistent with cavernous hemangioma (**Figure 1A** and **1B**). Immunohistochemical studies showed that CD34 stain highlighted the endothelial cells, thus confirming the diagnosis (**Figure 1C** and **1D**).

On follow-up, the surgical intervention produced a good outcome, and no changes were found in the uvula one year after the partial uvulectomy.

## DISCUSSION

Hemangiomas are the most common benign vascular tumors,<sup>2</sup> that can be acquired or congenital lesions and consist histologically of dilated blood vessels. They are divided into capillary hemangiomas, cavernous and mixed subtypes.<sup>3</sup> Capillary hemangiomas are well-circumscribed proliferation of small vessels lined by flattened endothelial cells, whereas cavernous hemangiomas are comprised of poorly circumscribed collections of large vessels with thickened walls.<sup>4</sup> Capillary hemangiomas are commonly present in infancy or first decade of life and spontaneously regress while cavernous hemangiomas are commonly observed as acquired lesions on the face, neck and trunk of middle-aged and older individuals and present as small (< 1

Received: 11/30/2014; Revised: 01/15/2015; Accepted: 01/18/2015

\*Corresponding Author: Clinical Lab, Medina Hospital, Quest Diagnostics, Medina, NY 14103. (Email: dr.frankchen@yahoo.com)

cm), bright-red, dome-shaped papules.<sup>4</sup> Hemangiomas of the oral cavity often involve frequently traumatized areas, such as the lip, buccal mucosa and lateral borders of the tongue.<sup>5</sup> While, hemangiomas involving the uvula are uncommon, cavernous hemangiomas observed exclusively in the uvula are extremely rare. To our knowledge, only four cases of uvula hemangiomas, excluding the case we are describing here, have been reported in literature.<sup>1,6,7</sup>

In this case report, we identified a rare case of cavernous hemangioma in a uvula based on its characteristic histological features and the result of CD34 immunostaining, which include poorly demarcated lesion with dilated blood vessels lined by flat endothelium showing CD34 immunoreactivity. Of the five reported cases, including ours, four of the patients are male and one female; all were adults. The symptoms include persistent cough, foreign body sensation, dysphagia, and daily snoring. Oral examination usually reveals an elongated or enlarged uvula, with purple appearance. Treatments include excisional biopsy in two cases, en bloc excision of hemangioma by CO2 laser in one case, total uvulectomy with radiofrequency knife in one case, and a partial uvulectomy in our case (**Table 1**).<sup>1,6,7</sup> All patients have good surgical outcomes, and the symptoms are relieved with no recurrence of hemangioma.

Typically, the differential diagnoses of lesions showing vascular and lymphatic proliferation in oral cavity include lymphangioma, Kaposi sarcoma, pyogenic granuloma, epithelioid hemangioma and angiosarcoma.<sup>1,6,8-12</sup> In relation to lymphangioma, the diagnosis can be assisted by the presence of intraluminal proteinaceous fluid with lymphocytes and red blood cells, and stromal lymphoid aggregates. Kaposi sarcoma consists of slit-like vascular spaces lined by bland flat and spindle endothelial tumor cells, with surrounding stroma infiltrated by lymphocytes and plasma cells. Demonstration of human herpesvirus-8 by in situ hybridization (ISH) and/or immunohistochemical stains

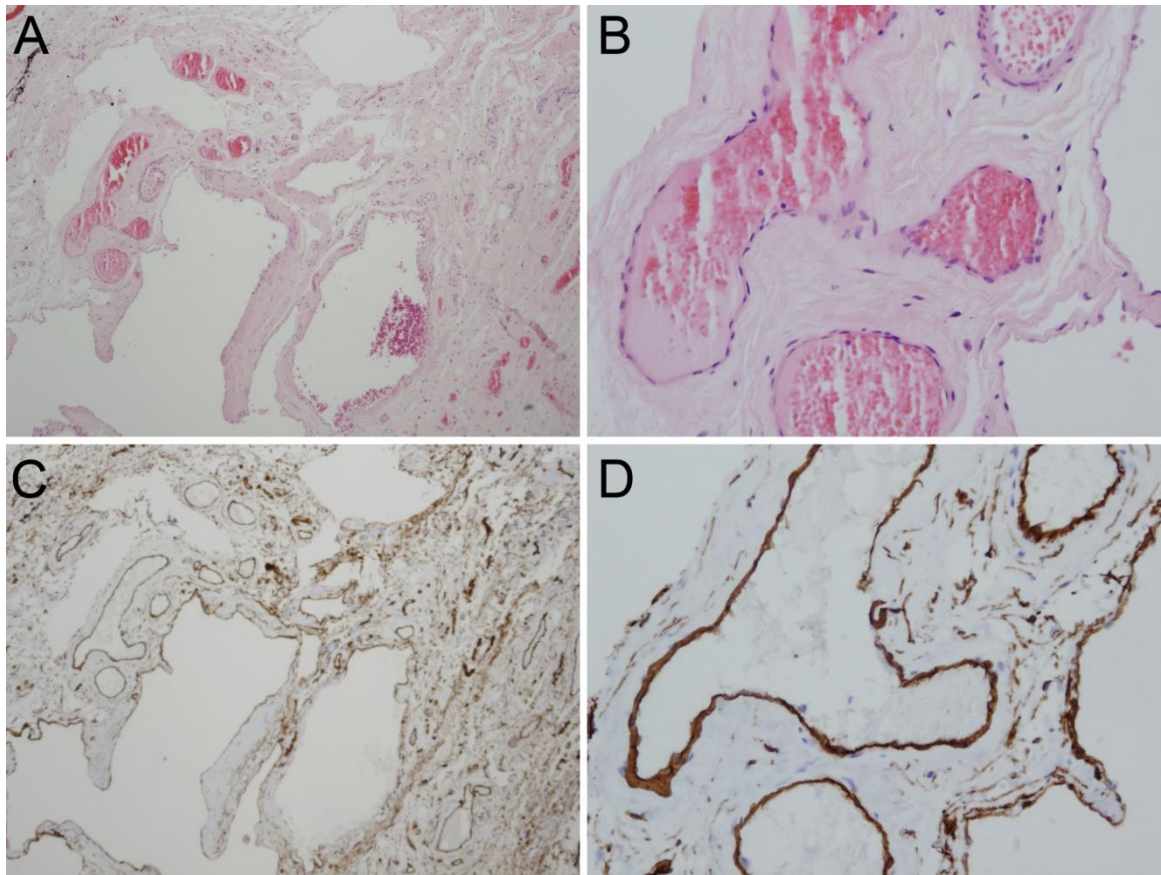
are helpful to confirm the diagnosis.<sup>13-15</sup> Pyogenic granuloma is a subtype of capillary hemangioma, which is commonly found in gingiva, lips, face and tongue. These polypoid friable lesions are easily bleeding and often ulcerated. Microscopically, the lobular vascular proliferation of pyogenic granuloma is composed of capillary-sized vessels lined by swollen endothelia. There is prominent edematous stroma with a mononuclear and neutrophil infiltrate, a feature which helps in the differential diagnosis. Epithelioid hemangioma is a vascular neoplasm with intermediate or low malignant potential. The presence of cytoplasmic vacuoles in endothelia and myxoid stroma in epithelioid hemangioma assists in differentiating this type of neoplasm from cavernous hemangioma. Finally, angiosarcoma is characterized by irregularly-shaped vascular spaces lined by atypical endothelial cells with hyperchromatic nuclei and high mitotic activity, which are malignant features absent in the benign lesion of cavernous hemangioma.

## CONCLUSION

In summary, our case report presents a rare case of cavernous hemangioma involving the uvula. We emphasize that cavernous hemangiomas in the oral cavity, though relatively uncommon, do occur and can even manifest as lesions in the uvula on very rare occasions. When oropharyngeal evaluation reveals a lesion in the oral cavity (including the uvula), the possibility of hemangioma should be taken into account. Reviewing previously reported cases suggests that uvular hemangiomas can be effectively treated through excision of the lesion or uvulectomy, providing symptomatic relief to persistent cough, foreign body sensation and loud snoring. The prognosis is excellent without reported recurrence supporting the need to accurately identify this entity and prevent overzealous surgical intervention. Finally, we recommend that hemangioma, although rare, should be considered in the differential diagnosis of vascular proliferative lesions involving oral cavity.

**Table 1.** Summary of reported cases in literature.

First Author and year reported	Age/Gender	Clinical presentations	Histological findings	Treatment	Follow-up duration
Sorbrinhol F (2003) <sup>6</sup>	21y M	Sensation of foreign body in the throat for 2 years, oropharyngeal dysphagia	Ectasic vessels, thin vascular wall, intertwined with fibrous tissue	Total uvulectomy with radiofrequency knife	Not reported
Thong JF (2008) <sup>7</sup>	30y M	Daily snoring and excessive day time somnolence	Not available	En bloc excision of the hemangioma by CO2 laser	3 month
Thomas R (2009) <sup>1</sup>	54y F	Persistent cough and foreign body sensation in the throat for 10 years and spitting of blood stained saliva for 2 weeks	Numerous dilated vascular spaces with back-to-back arrangement and no intervening neural parenchyma	Excisional biopsy of uvula	Not reported
	24y M	Chronic cough and foreign body sensation in the throat for 1 year		Excisional biopsy of uvula	Not reported
Wang M (2014) (current case)	58y M	Presented with a discolored uvula mass	poorly demarcated lesion with dilated blood vessels lined by flat endothelium showing CD34 immunoreactivity	partial uvulectomy	12 month



**Figure 1.** Morphological and immunohistochemical features of the uvular mass, consistent with cavernous hemangioma. (A) The mass is comprised of dilated vascular spaces filled with red blood cells. (B) High magnification demonstrates these vascular spaces are lined by flat endothelial cells with no nuclear atypia or mitotic figures. (C) CD34 immunohistochemical stain highlights the flat endothelial cells lining the vascular spaces. (D) High magnification showing diffuse and strong CD34 immunostaining. A, C: H&E, magnification x40, B, D: H&E, magnification x200.

#### CONFLICT OF INTEREST

The authors have no conflict of interest to disclose.

#### REFERENCES

1. Thomas R, Ramalingama SBJ, Samuela J, Kumara KD. Cavernous hemangioma of the uvula – A Case Report. *Sri Ramachandra Journal of Medicine*. 2009;1:36-37.
2. McGill TJI FJ, Mulliken JB. Hemangiomas and vascular anomalies of the head and neck. In: Cummings CW FJ, Harker LA, Krause CJ, Richardson MA, Schüller DE, ed. *Otolaryngology-Head and Neck Surgery* 3rd ed. St Louis: Mosby; 1998:66-80.
3. Hassard AD, Byrne BD. Arteriovenous malformations and vascular anatomy of the upper lip and soft palate. *Laryngoscope*. 1985;95:829-832.
4. Gattuso P, Reddy VB, David O, Spitz DJ. *Differential Diagnosis in Surgical Pathology*. 2nd ed. Philadelphia, PA: Saunders; 2009.
5. Woods WR, Tulumello TN. Management of oral hemangioma. Review of the literature and report of a case. *Oral Surg Oral Med Oral Pathol*. 1977;44:39-44.
6. G. Sobrinho FP, Felix MA, Valle AC, Lessa HA. Hemangioma of uvula: one case report. *Brazilian Journal of Otorhinolaryngology*. 2003;69:571-574.
7. Thong JF, Pang KP, Siow JK. Haemangioma of the uvula causing loud habitual snoring—a rare entity. *Med J Malaysia*. 2008;63:408-409.
8. Arribas-Garcia I, Dominguez MF, Alcalá-Galiano A, Garcia AF, Valls JC, De Rasche EN. Oral primary angiosarcoma of the lower lip mucosa: report of a case in a 15-year-old boy. *Head Neck*. 2008;30:1384-1388.
9. Nagata M, Yoshitake Y, Nakayama H, et al. Angiosarcoma of the oral cavity: a clinicopathological study and a review of the literature. *Int J Oral Maxillofac Surg*. 2014;43:917-923.
10. Rosai J. *Rosai and Ackerman's Surgical Pathology*. 10th ed: Mosby; 2011.
11. Gordon-Nunez MA, Silva e M, Lopes MF, de Oliveira-Neto SF, Maia AP, Galvao HC. Intraoral epithelioid hemangioendothelioma: a case report and review of the literature. *Med Oral Patol Oral Cir Bucal*. 2010;15:e340-346.
12. Sunil S, Gopakumar D, Sreenivasan BS. Oral lymphangioma - Case reports and review of literature. *Contemp Clin Dent*. 2012;3:116-118.
13. Cheuk W, Wong KO, Wong CS, Dinkel JE, Ben-Dor D, Chan JK. Immunostaining for human herpesvirus 8 latent nuclear antigen-1 helps distinguish Kaposi sarcoma from its mimickers. *Am J Clin Pathol*. 2004;121:335-342.
14. Patel RM, Goldblum JR, Hsi ED. Immunohistochemical detection of human herpes virus-8 latent nuclear antigen-1 is useful in the diagnosis of Kaposi sarcoma. *Mod Pathol*. 2004;17:456-460.
15. Staskus KA, Zhong W, Gebhard K, et al. Kaposi's sarcoma-associated herpesvirus gene expression in endothelial (spindle) tumor cells. *J Virol*. 1997;71:715-719.