

**Case Report**

# Cecal Bascule after Colonoscopy - Case Report and Review of Literature

Nihar Shah, MD;<sup>1,2+</sup> Hiren Patel, MD;<sup>3,5+\*</sup> Varun Patel, MD;<sup>2,4</sup> Robert Spira, MD<sup>1,2</sup>

<sup>1</sup>Department of Gastroenterology, Saint Michael's Medical Center, Newark, NJ

<sup>2</sup>School of Health and Medical Sciences, Seton Hall University, South Orange, NJ

<sup>3</sup>Department of Internal Medicine, Saint Joseph's Regional Medical Center, Paterson, NJ

<sup>4</sup>Department of Internal Medicine, Saint Michael's Medical Center, Newark, NJ

<sup>5</sup>New York Medical College, Valhalla, NY

**Cecal bascule is a rare disease variant of a cecal volvulus. It consists of upward and anterior folding of the ascending colon, forming a flap valve, and occluding the bowel lumen resulting in proximal cecal dilatation. Herein, we present a case of a patient who developed persistent abdominal pain few hours after a colonoscopy. CT scan of the abdomen revealed an upward and anterior folding of the cecum. Subsequently the patient was taken to the operating room for a right hemi-colectomy. This case emphasizes the importance to consider cecal bascule as a differential diagnosis in patients with persistent abdominal pain after colonoscopy, considering the ease of diagnosis with imaging studies and emergent surgical correction. [N A J Med Sci. 2015;8(3):143-145. DOI: 10.7156/najms.2015.0803143]**

**Key Words:** *cecal bascule, cecal volvulus, colonoscopy complications, abdominal pain*

## INTRODUCTION

Cecal bascule is a variant of the cecal volvulus, which consists of an upward and anterior folding of the ascending colon. The incidence of cecal volvulus is reported to be 2.8 to 7.1 per 100,000 annually; one-fourth of all cases of colonic volvulus.<sup>1-3</sup> Only 10% of cecal volvulus and estimated 0.2% of all intestinal obstructions are cecal bascules.<sup>4,5</sup> It is more common in women and during the sixth decade at presentation.<sup>6,7</sup> No case reports of cecal bascule and only four cases of cecal volvulus after colonoscopy were reported in the literature.<sup>8-11</sup> As in our case, the authors did not have difficulty negotiating through the colon and did not require a prolonged colonoscopy time. Herein, we present a unique case of a cecal bascule after colonoscopy.

## CASE PRESENTATION

Our patient is a 72-year-old Nigerian male with past medical history of asthma, hypertension, malaria, prostate cancer status post chemotherapy admitted to the hospital for uncomplicated diverticulitis. After three days of intravenous antibiotics, patient was discharged home on oral antibiotics and scheduled for an outpatient colonoscopy in 4 weeks. The colonoscopy revealed a very small and superficial ulcer with no active bleeding and unremarkable surrounding mucosa, which required no intervention. In addition, the left colon revealed severe diverticulosis and a single small polyp in the

rectum, which was removed by cold biopsy polypectomy. The entire procedure took only eleven minutes, with no major resistance or difficulty encountered during the procedure. After the procedure the patient was discharged home in stable condition.

Few hours after the colonoscopy, the patient began having progressive right upper quadrant abdominal pain. The pain was persistent and there was no improvement in the pain even the next morning which caused him to come to the Emergency Department. The pain was described as sharp, continuous, worsened with movement and food intake, and associated with nausea. The patient denied any fevers, abdominal trauma, vomiting, and other bowel or bladder disturbances. The patient denied smoking cigarettes, drinking alcohol or using illicit drugs. The patient has no past surgical history. Vital signs were within normal limits. The abdominal examination revealed tenderness in the epigastric, right upper, and right lower quadrant without any guarding, rigidity or rebound tenderness. Rest of the physical exam was grossly normal.

Complete blood count, lactic acid, liver function tests, and kidney function were within normal limit. A CT scan of the abdomen with PO contrast was done which showed, diverticulosis and an anterior and upward folding of the cecum with dilation and surrounding fat stranding without any signs of bowel perforation (**Figure 1, Figure 2**).

The patient was then scheduled for emergency laparoscopy due to persistent pain. During the laparoscopy, CT scan

Received: 04/25/2015; Revised: 07/13/2015; Accepted: 07/22/2015

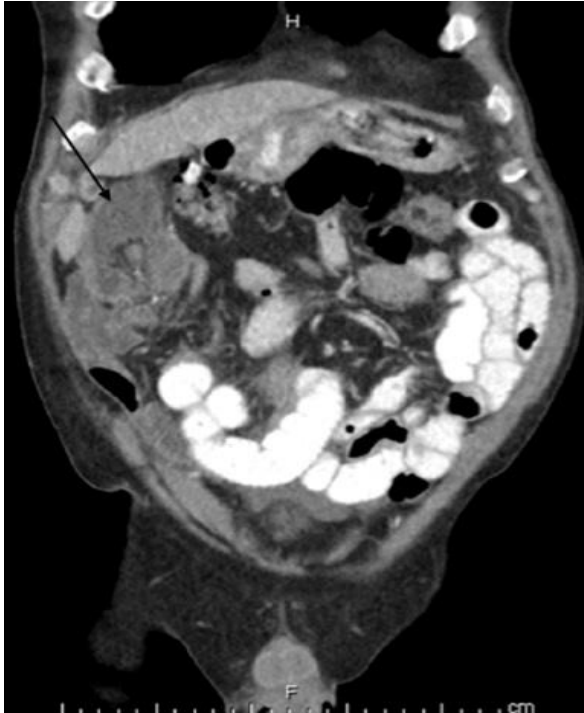
+ Both authors have contributed for this paper equally

\*Corresponding Author: Department of Internal Medicine, New York Medical College, St. Joseph's Regional Medical Center, Paterson, NJ.  
Tel: 973-754200-0106.

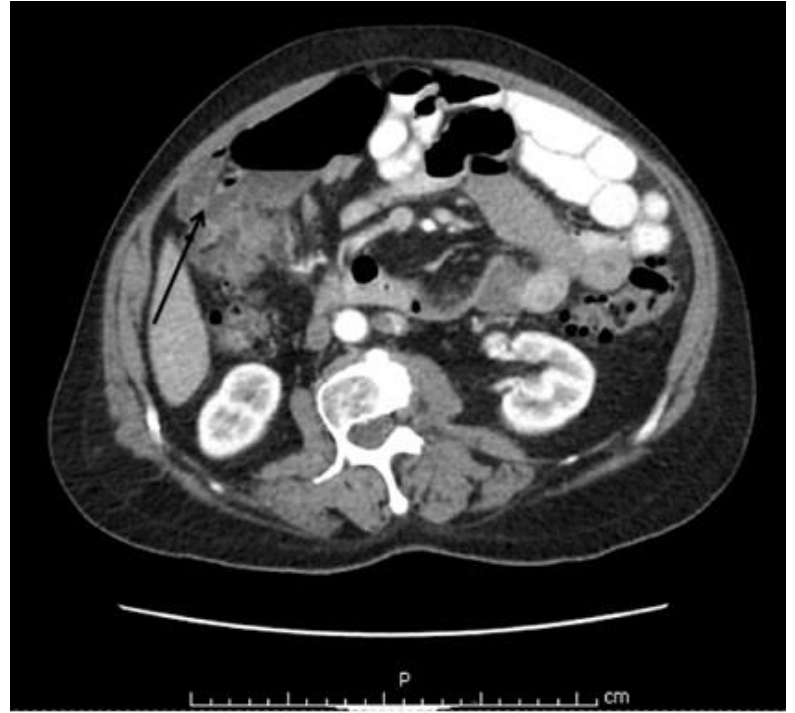(Email: hiren727@gmail.com)

findings were confirmed and a right hemi-colectomy was performed. Other than diverticulosis no other abnormality was seen in the terminal ileum, transverse, and descending colon. The specimen was sent for pathology. On pathology examination, an approximately 1.5 cm ulcer was seen in the cecum. On microscopic examination, acute necrotizing

inflammation was seen in the ulcerated area and the adjacent colon showed foci of early transmural congestion with submucosal and subserosal hemorrhages. Post operatively, the patients abdominal pain improved and after a few days of inpatient monitoring, was discharged home in stable condition.



**Figure 1.** Coronal view of the computed tomography of the abdomen with PO contrast shows anterior folding of the cecum (white asterisk) in the right upper quadrant of the abdomen corresponding to the site of the patients abdominal pain. The proximal small intestine is dilated (white arrow) with remnant PO contrast (black arrows).



**Figure 2.** Axial view of the computed tomography of the abdomen with PO contrast shows proximal dilatation of cecum (white arrow) with remnant PO contrast in the small bowel (black arrow).

## DISCUSSION

In 1899, Treves first described a cecal bascule, which in French means ‘seesaw’ or ‘counterbalanced bridge’.<sup>12</sup> Later in 1938, Weinstein reclassified cecal bascule as a type of cecal volvulus.<sup>13</sup> There are three types of cecal volvulus. Type 1 and Type 2 cecal volvulus develop from clockwise and counterclockwise rotation of the cecum, respectively. The cecum rotates around its mesentery including the ascending colon and terminal ileum. Type 3 cecal volvulus, also known as cecal bascule, involves the upward and anterior folding of the cecum. As a result, the distal part of the cecum found at the ileocecal junction rotates to where its posterior surface becomes the anterior. Bending of the bowel segment forms a flap valve, which occludes the bowel lumen and causes massive proximal cecal dilatation. However, cecal bascule does not result in axial torsion of the cecum, which helps differentiate the entity from Type 1 and Type 2 cecal volvulus.

Cecal volvulus is dependent upon the previous existence of inadequate fixation of cecum. During embryogenesis, failure of the cecum to fix to the posterior abdominal wall leads to a

mobile cecum that can predispose to cecal volvulus.<sup>14</sup> Normally, intestinal content passes from the ileum into the cecum in an antegrade fashion. When a flap valve occlusion occurs at the ascending colon, intestinal content accumulates in the cecum. In the presence of a competent ileo-cecal valve, retrograde decompression of intestinal content back to the terminal ileum is not possible, which results in profound cecal dilatation. Bacterial metabolism and digestive products produce gas that worsens the cecal dilation. Consequently, cecal dilation triggers constriction of the venous and capillary network of the right hemi-colon resulting in possible ischemic changes.<sup>14</sup>

Precipitating or predisposing factors have been described for cecal volvulus including constipation, high fiber diet, pregnancy, pelvic tumor, ileus, obstructing distal bowel lesions, mechanical ventilation, and previous intra-abdominal surgery.<sup>15,16</sup> Colonoscopy may also be considered a precipitating factor in patients who have mobile cecum due to failure to fixate to the posterior abdominal wall. In such patients with a mobile cecum, colonoscopy manipulation and

air insufflation may cause displacement of the cecum and ultimately lead to cecal volvulus. In our patient, the increased motility related to the colonoscopy prep may have initiated the rotation of the cecum and lead to mild ischemic changes in the cecum leading to ulcer formation. The manipulation and air insufflation during colonoscopy likely caused worsening of the rotation of the cecum leading to constriction of venous and capillary networks, which would account for the severe persistent abdominal pain in the patient.

Most patients with a cecal bascule present with a gradual onset of abdominal pain that develops over the period of hours to days associated with nausea, vomiting, and/or obstipation. The clinical presentation can be highly variable ranging from insidious, intermittent episodes of abdominal pain to an acute abdominal catastrophe.<sup>2,3,14-16</sup> Physical examination also varies depending upon the severity of the underlying volvulus and its complications including perforation or ischemic bowel. Upright abdominal x-ray, computed tomography of the abdomen, single contrast barium or hypaque enema, and laparoscopy/laparotomy can be done to diagnose cecal bascule/volvulus. Plain X-ray findings usually reveal a distended cecum. Computed tomography of the abdomen confirms the diagnosis in around 90% of patients showing upward folding of the cecum.<sup>17,18</sup> Contrast studies typically reveal a rounded termination of contrast as a result of the transversely folded cecum. Management is mainly surgical including cecectomy, cecectomy or right hemicolectomy. Cecectomy alone has a high risk of leakage and recurrence. Cecectomy has been associated with a high risk of postoperative wound infection. Therefore, some authors recommend right hemi-colectomy as the mainstay treatment for cecal volvulus/bascule.<sup>6,19</sup> There is a 20-25% risk of concurrent cecal necrosis and a failure rate of around 95% with non-operative management such as colonoscopy or reduction barium enema; thus they are not recommended.<sup>20</sup>

## CONCLUSION

Cecal bascule is a very rare disease entity, which causes large bowel obstruction and complications of cecal necrosis/perforation. It is imperative to consider cecal bascule as a differential diagnosis after colonoscopy when a

patient presents with persistent and/or worsening abdominal discomfort.

---

## CONFLICT OF INTEREST

The authors have no conflict of interest to disclose.

---

## REFERENCES

1. Katoh T, Shigemori T, Fukaya R, Suzuki H. Cecal volvulus: report of a case and review of Japanese literature. *World J Gastroenterol.* 2009;15:2547-2549.
2. Consorti ET, Liu TH. Diagnosis and treatment of caecal volvulus. *Postgrad Med J.* 2005;81:772-776.
3. Oza V, Johnson A, Pfeil S. Cecal bascule: an unusual pathology of cecal dilation. Case report and brief review. *J Interv Gastroenterol.* 2013;3:143-144.
4. Rabinovici R, Simansky DA, Kaplan O, Mavor E, Manny J. Cecal volvulus. *Dis Colon Rectum.* 1990;33:765-769.
5. Haskin PH, Teplick SK, Teplick JG, Haskin ME. Volvulus of the cecum and right colon. *JAMA.* 1981;245:2433-2435.
6. O'Mara CS, Wilson TH Jr, Stonesifer GL, Stonesifer GL, Cameron JL. Cecal volvulus: analysis of 50 patients with long-term follow-up. *Ann Surg.* 1979;189:724-731.
7. Ballantyne GH, Brandner MD, Beart RW, Ilstrup DM. Volvulus of the colon. Incidence and mortality. *Ann Surg.* 1985;202:83-92.
8. Amidon PB, Story RK. Cecal volvulus after colonoscopy. *Gastrointest Endosc.* 1993;39:105.
9. Anderson JR, Spence RA, Wilson BG, Hanna WA. Gangrenous caecal volvulus after colonoscopy. *Br Med J (Clin Res Ed).* 1983;286:439-440.
10. Viney R, Fordan SVE, Fisher WE, Ergun G. Cecal volvulus after colonoscopy. *Am J Gastroenterol.* 2002;97:3211-3212.
11. Radin DR, Halls JM. Cecal volvulus: a complication of colonoscopy. *Gastrointest Radiol.* 1986;11:110-111.
12. Treves F. *Intestinal Obstruction.* W Wood Company, New York. 1899:135.
13. Weinstein M. Volvulus of cecum and ascending colon. *Ann Surg.* 1938;107:248-259.
14. Bobroff LM, Messinger NH, Subbarao K, Beneventano TC. The cecal bascule. *Am J Roentgenol Radium Ther Nucl Med.* 1972;115:249-252.
15. Pousada L. Cecal bascule: an overlooked diagnosis in the elderly. *J Am Geriatr Soc.* 1992;40:65-67.
16. Thangasamy I, Silcock R. Caecal bascule: a rare complication following emergency caesarean section. *J Surg Case Rep.* 2010;2010:8.
17. Delabrousse E, Sarliève P, Saille N, Aubry S, Kastler BA. Cecal volvulus: CT findings and correlation with pathophysiology. *Emerg Radiol.* 2007;14:411-415.
18. Swenson BR, Kwaan MR, Burkart NE, et al. Colonic volvulus: presentation and management in metropolitan Minnesota, United States. *Dis Colon Rectum.* 2012;55:444-449.
19. Ellis H. *Intestinal Obstruction.* Appleton-Century-Crofts; New York. 1982.
20. Hodin RA, Weiser M, Collins KA. Cecal Volvulus. UptoDate. <http://www.uptodate.com>. July 11, 2015.